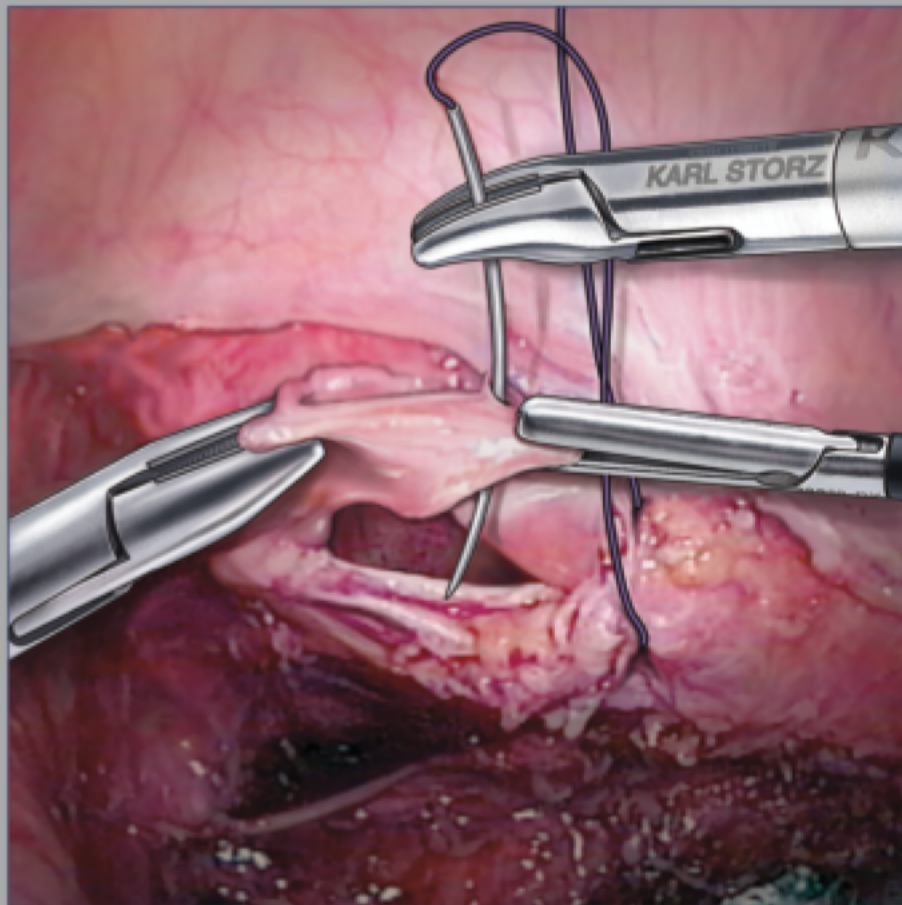


LAPAROSCOPIC SUTURING IN THE VERTICAL ZONE™




Charles H. KOH, MD, FRCOG, FACOG

**Reproductive Specialty Center
Milwaukee, Wisconsin, U.S.A.**

LAPAROSCOPIC SUTURING IN THE VERTICAL ZONE™

Charles H. KOH, MD, FRCOG, FACOG

Reproductive Specialty Center Milwaukee,
Wisconsin, U.S.A.



Charles H. Koh, MD, FRCOG, FACOG

About the Author:

Dr. Koh specializes in advanced laparoscopic surgery and has created many innovations and techniques to further the field. He lectures and performs demonstration surgeries around the world at international meetings and courses. Dr. Koh also holds patents for a laparoscopic hysterectomy technique, "Simplifying Total Laparoscopic Hysterectomy"

(U.S. patent #5520698, May 28, 1996) and a device for aiding the operation, "KOH Colpotomizer Pneumo Occluder, Vaginal Extender for Colpotomy" (U.S. Patent #5643285, July 1, 1997).

Working with KARL STORZ, Dr. Koh helped design the KOH Ultramicro Instruments described in this monograph. To this day, the KOH Ultramicro series is the only set of instruments available for laparoscopic microsurgery. KOH Ultramicro Instruments have enabled surgeons to perform laparoscopic tubal reversal and their use has been widely adopted in pediatric laparoscopy, general surgery and vascular surgery.

The recent successful introduction of the KOH Macro Needle Holder and helper now allows a complete spectrum of suturing needs from microsurgery to bariatric and general surgery to be accomplished.

Please note:

Medical knowledge is constantly changing. As new research and clinical experience broaden our knowledge, changes in treatment and therapy may be required. The authors and editors of the material herein have consulted sources believed to be reliable in their efforts to provide information that is complete and in accordance with the standards accepted at the time of publication. However, in view of the possibility of human error by the authors, editors, or publisher of the work herein, or changes in medical knowledge, neither the authors, editors, publisher, nor any other party who has been involved in the preparation of this work, can guarantee that the information contained herein is in every respect accurate or complete, and they cannot be

Laparoscopic Suturing in the Vertical Zone™

Charles H. Koh, MD, FRCOG, FACOG
Reproductive Specialty Center
Milwaukee, Wisconsin USA

Contact:

Charles H. Koh, MD, FRCOG, FACOG
2315 North Lake Drive, Suite 501
Milwaukee, Wisconsin 53211
U.S.A.
Phone: +1 414 289 - 9668
Fax: +1 414 289 - 0974
E-mail: information@ReproductiveCenter.com
CKoh@ReproductiveCenter.com
Web: www.ReproductiveCenter.com

Copyright:

© 2013 Published by **Endo:Press®**, Tuttlingen
ISBN 978-3-89756-519-7, Printed in Germany
P.O. Box, D-78503 Tuttlingen, Germany
Phone: +49 7461/14590
Fax: +49 7461/708-529
E-mail: Endopress@t-online.de

Editions in languages other than English and German are in preparation. For up-to-date information, please contact **Endo:Press®** Tuttlingen, Germany, at the address indicated above.

Typesetting and Lithography:

Endo:Press® Tuttlingen, D-78503 Tuttlingen, Germany

Printed by:

Straub Druck+Medien AG,
D-78713 Schramberg, Germany

All color illustrations were made by:

Jennifer Fairman,
Fairman Studios, LLC
681 Main Street, Suite 2-11,
Waltham, Massachusetts 02451, U.S.A.

02.13-1

All rights reserved. No part of this publication may be translated, reprinted or reproduced, transmitted in any form or by any means, electronic or mechanical, now known or hereafter invented, including photocopying and recording, or utilized in any information storage or retrieval system without the written prior permission from the copyright holder.

held responsible for any errors or omissions or for the results obtained from use of such information. The information contained within this brochure is intended for use by doctors and other health care professionals. This material is not intended for use as a basis for treatment decisions, and is not a substitute for professional consultation and/or use of peer-reviewed medical literature. Some of the product names, patents, and registered designs referred to in this booklet are in fact registered trademarks or proprietary names even though specific reference to this fact is not always made in the text. Therefore, the appearance of a name without designation as proprietary is not to be construed as a representation by the publisher that it is in the public domain.

Contents

1.0 Introduction	6
1.1 What is the Vertical Zone™?	6
1.2 Why the Vertical Zone™?	6
2.0 Laparoscopic Macrosuturing.....	7
2.1 The Macro-Needle Holder.....	7
2.2 Handle Grip and Release.....	7
2.3 Dismantling Instruments –	
Three independent components for optimal cleaning results.....	7
3.0 Laparoscopic Suturing Technique in the Vertical Zone™	8
3.1 Ports	8
3.2 Surgeon Position and Monitors	8
Port Positions	9
3.3 Suturing.....	10
3.4 ‘Smiley’ Needle Knot-Tying	12
3.5 Expert Knotting	19
3.6 Cinch Knot.....	27
3.7 Continuous Suturing.....	31
4.0 Laparoscopic Microsuturing	32
4.1 KOH Ultra-Micro Instrumentation.....	32
4.2 Magnification and Resolution	33
4.3 Microsutures.....	33
5.0 Vertical Zone™ Suturing Techniques in Advanced Laparoscopic Surgery.....	34
5.1 Partial Cystectomy for Infiltrative Endometriosis	34
5.2 Repair of Bladder Damage at Total Laparoscopic Hysterectomy.....	37
5.3 Full Thickness Disc Resection of Rectal Endometriosis	
Involving Muscle and Mucosa.....	40
5.4 Repair of through-and-through Trocar Injury of Ileum	
using 6-0 Prolene BV-1 Needle, KOH Ultramicro Instrumentation	43
5.5 Tubocornual Anastomosis Secondary to Fibrosis	45
5.6 Laparoscopic Cystoureterostomy Secondary to Ureteral Damage	
After Hysterectomy	49
5.7 Myomectomy – Anterior Intramural Fibroid Measuring 7 cm.....	53
5.8 Neosalpingostomy Hydrosalpinx.....	56
Suggested Reading.....	58
Laparoscopic Ultramicrosurgery	58
KOH Macro Needle Holders	59

“We are what we repeatedly do.
Excellence, then, is not an act, but a habit.”

Aristotles

“Adept and successful laparoscopic suturers
are made, not born.”

Charles H. Koh

Suturing in the Vertical Zone™

Our style of suturing differs from all existing techniques because the needle rotates in the sagittal plane of the body. From the vantagepoint of the laparoscope, the needle appears to be traversing from top to bottom vertically, hence the 'Vertical Zone™' terminology. All other suturing styles taught to date employ central port positions where the needle traverses from side-to-side and where each suturing motion is a unique adventure in itself. The Vertical Zone™ technique specifies port positions that allow a horizontal attitude of the needle holder shaft, which then rotates axially to move the needle in the sagittal plane. This axial rotatory movement totally eliminates the pivot effect of the

trocars. The act of needle-driving is constant and always starts from the top, moving vertically downwards. The surgeon throws knots from a two-handed ipsilateral position, always using the same motion. The arms and elbows are totally relaxed in this style of suturing, which closely resembles open laparotomy. The port positions, suturing style and closely choreographed technique all comprise what we call "Laparoscopic Suturing in the Vertical Zone™." It is this constancy of choreography in the technique that allows for successful acquisition of skill by residents, fellows and others. When the surgeon finally 'enters the zone,' he or she will execute ipsilateral sutures at a fast, rhythmic – almost mesmerizing – pace.



1.0 Introduction

The ability to perform laparoscopic suturing to a meaningful degree is an indispensable component of advanced operative laparoscopy. The evolution of laparoscopy has been marked by several distinct phases and enabling technologies:

Phase 1:

Diagnostic laparoscopy.

Phase 2:

Operative laparoscopy, starting with coagulation and progressing to lysis and removal of diseased viscus using hemostatic devices. The so-called 'one armed surgeon' was a prominent feature of this phase, as surgeons had to dedicate one hand to holding the laparoscope.

Phase 3:

The third or current phase of laparoscopy is largely reconstructive, introducing a variety of procedures that require suturing. The recent introduction of robotic surgery has also played a role in highlighting the importance of suturing in advanced procedures across all specialties. The use of two hands for operating is very much a feature of this advanced phase of laparoscopic surgery.

Laparoscopic Suturing

Suturing and knot tying are typically considered the most difficult of the laparoscopic skills to be acquired. The technique that we will describe in the forthcoming pages has been put to the test in both our inanimate and animate labs. After four hours of intensive training, residents who have never performed laparoscopic suturing are able to master the skill.

In our efforts to advance laparoscopic suturing, we have been uncompromising in insisting that the technique never be "substandard" for the sake of laparoscopic expediency. To that end, we have studied the mechanics of laparoscopic suturing from a goal-oriented standpoint.

- The action should be transparent to the surgeon and feel "just like suturing at laparotomy"
- It should also be universal: all tasks ranging from the single interrupted, continuous and purse string suture to cinch-knot tying must be readily attainable from this uniform approach

First, we determined that a curved needle moving in the sagittal plane achieves all of these goals. We then derived the port positions that would facilitate this needle plane. These same port positions also need to be practical for performing all operative dissections and procedures preceeding suturing. The culmination of these concepts is the ipsilateral two-handed approach for laparoscopic surgery and suturing, or what we call the 'Vertical Zone™.'

It gives us great satisfaction to share this technique with you. Our goal is to propel laparoscopic surgeons to the next level of advanced operative laparoscopy which will minimize or eliminate the need to "open" the patient to repair any accidental visceral injury during laparoscopic surgery.

1.1 What is the Vertical Zone™?

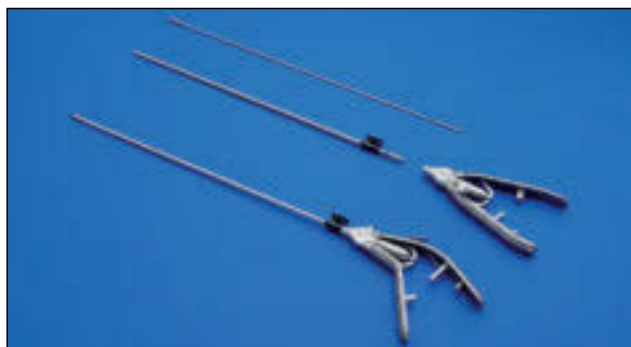The Vertical Zone™ refers to the sagittal plane that the curved needle moves through during suturing. It happens to be the most common plane at laparotomy and easily replicated at laparoscopy using our technique.

1.2 Why the Vertical Zone™?

- Effective and accurate needle-driving for all suturing needs without the limitations imposed by laparoscopy
- A technique that most closely resembles relaxed suturing at laparotomy
- Reduces fatigue from repetitive suturing
- Easy to teach and master
- Does not require any complex or specialized tools other than a high-quality needle holder

2.0 Laparoscopic Macrosuturing

2.1 The Macro-Needle Holder



Note: All references below are for a right-handed surgeon standing on the right side of the patient while operating in the pelvis. The same descriptions apply for a right-handed surgeon standing on the left side of the patient and operating in the upper abdomen.

Jaw Curved left

Allows the needle to be grasped by the jaw at an optimal position of 135° to the shaft. There is also an increased mechanical advantage during axial rotation of the shaft while needle-driving. Finally, the curved tip facilitates intracorporeal knot-tying. No “helper” instrument is needed for intracorporeal knot-tying.



Curved right

This needle holder can also be used in the left hand to assist in conjunction with the left curved jaw in intracorporeal knot tying. It is also occasionally used when one wishes to have the needle angle increased to more than 135° when standing on the patients left.

Straight

Used by surgeons who prefer extracorporeal knot-tying as the primary means of producing knots. Intracorporeal knot-tying is possible if the needle is held in a ‘smiley’ position (see Figs. 7–9).

Handle An ergonomic handle design facilitates hand and forearm positioning with ultra-lateral ports. The bend is also useful for those surgeons who prefer more medial ports for laparoscopic surgery and suturing.

2.2 Handle Grip and Release

1 The continuously tightening ratchet allows a choice of jaw pressure for accommodating BV, SH or CT-1 needles without damaging any of them.

2 The release mechanism is a great improvement over other models that employ a double-click for release since excessive effort is often needed for this to occur. This may cause the needle to fly off the tissue or the rubber glove to be trapped in the click mechanism.



3 Sufficient jaw pressure is available such that a CT 1 needle can be driven through Cooper’s ligament without the needle being displaced. Since the lateral port position eliminates the fulcrum effect, axial rotation of the shaft of the needle holder allows the needle to move in the sagittal plane (Vertical Zone™), providing very little lateral resistance when correctly applied. Ultra high-pressure needle holders of the early days (e.g., Cook) are no longer required.

4 Tungsten carbide inserts represent a key refinement of the jaw. While being extremely strong in holding the needle, they are also gentle and atraumatic on braided sutures. As a result, knot-tying can be achieved without fraying the suture.

5 Using the handle for rotation of the shaft also provides a mechanical advantage in needle driving, somewhat like using a ‘winch.’



2.3 Dismantling Instruments – Three independent components for optimal cleaning results

In this era of rising nosocomial infection rates and widespread introduction of central sterilization services in hospitals, cleaning and sterilization are becoming ever more important.

As in the case for any surgical instrument, the cleaning and hygiene of laparoscopic needle holders are essential. To meet all hygiene criteria the Macro-Needle Holder can be dismantled into three parts. The handle, outer sheath and insert can be cleaned and sterilized separately for perfect results.

The dismantling KOH macro needle holders feature the same effectiveness and precision users have come to expect, with significantly improved cleaning results achieved by dismantling the instrument.

3.0 Laparoscopic Suturing Technique in the Vertical Zone™

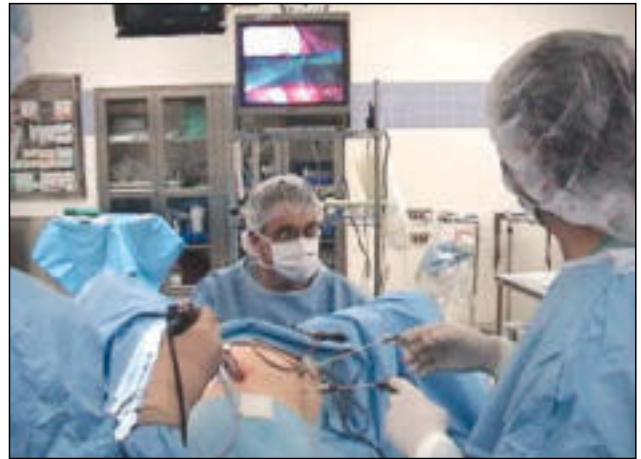3.1 Ports

Medial or central port locations do not provide for an effective suturing position. Nor are they very effective for two-handed ipsilateral operating. In fact, they are remnants of early diagnostic laparoscopy where the sole purpose of the suprapubic port was to move around the fallopian tubes for display of the pelvis. Today, a good uterine manipulator takes care of anteverting the uterus without the need for a central port. Similarly, it is common to see accessory central trocars in the “bikini line” to allow several instruments to be introduced while maintaining the bikini cosmetics. However, these accessory trocar site positions are a throwback to a time when only diagnostic and rudimentary laparoscopic surgery was being performed. Today, when advanced surgery is being performed via laparoscopy, these port positions are antiquated. The most effective port positions are ultralateral, as shown in the diagram. After insufflation of the abdomen, the lower ports are chosen at points 1–2 cm medial to the anterior superior iliac spine and lateral to the inferior epigastric vessels. The line corresponds to the anterior axillary line. The para-umbilical lateral port is at the same lateral line as the lower quadrant port, or even more lateral in the case of an obese patient. During insertion under vision, we ensure that it is superior to the ascending colon (see **Fig. 1**).

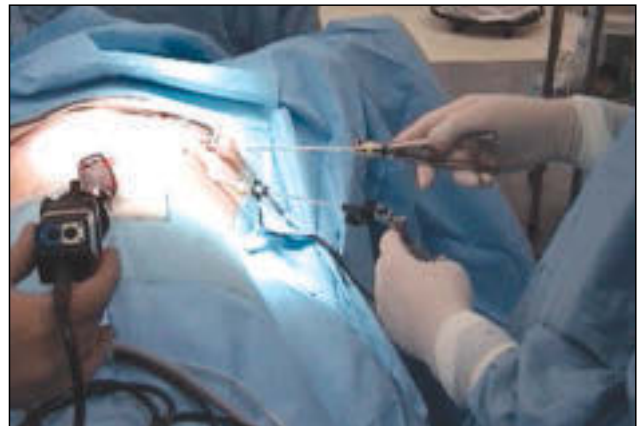For the surgeon standing on the right side of the patient, the ports as described in **Fig. 1** are applicable; for the surgeon standing on the left, **Fig. 2** is applicable. In **Fig. 1**, the assistant holds the laparoscope with his/her right hand and an instrument in the left lower port with the left hand. For intensive suturing, a 10 – 12 trocar is used in the right lower quadrant to facilitate introduction of the CT-1 needle. A adaptor that allows the 5 mm shaft of the needle holder to be used without loss of gas is ideal. For less intensive suturing, the CT needle can be introduced through the 5 mm port by a special technique.

3.2 Surgeon Position and Monitors

The following diagrams illustrate monitor placement and the position of the surgeon when operating from the patient's right.



This shows the ultra lateral port positions that allow the horizontal shaft and vertical zone technique for suturing and dissecting. The monitor is at the foot of the bed.



Note the horizontal needle holder and horizontal position of the forearm. The elbow is relaxed and adducted against the side of the surgeon's body. This position provides a more comfortable, less fatiguing effort at laparoscopic suturing. The horizontal needle holder shaft enables needle excursion in the sagittal plane. Compare the relatively similar position of the forearm, elbow and needle holder at laparotomy.

Port Positions

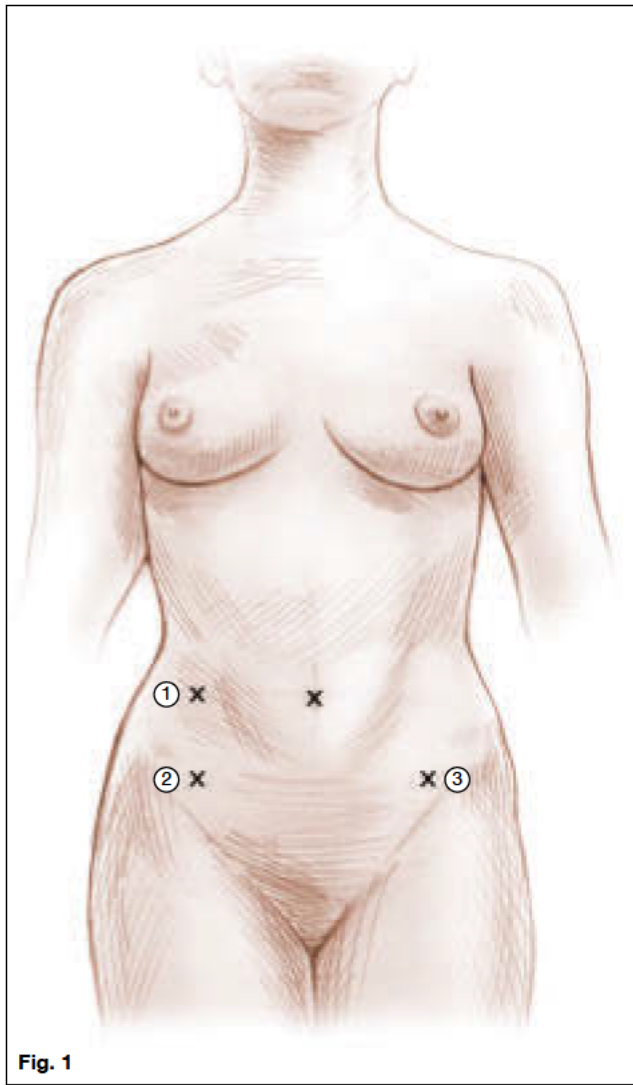


Fig. 1

Surgeon standing on patient's right side.

Port 1:

5 mm port sites

Port 2:

A 10-12 mm port is used here for intensive suturing

Port 3:

5 mm port sites

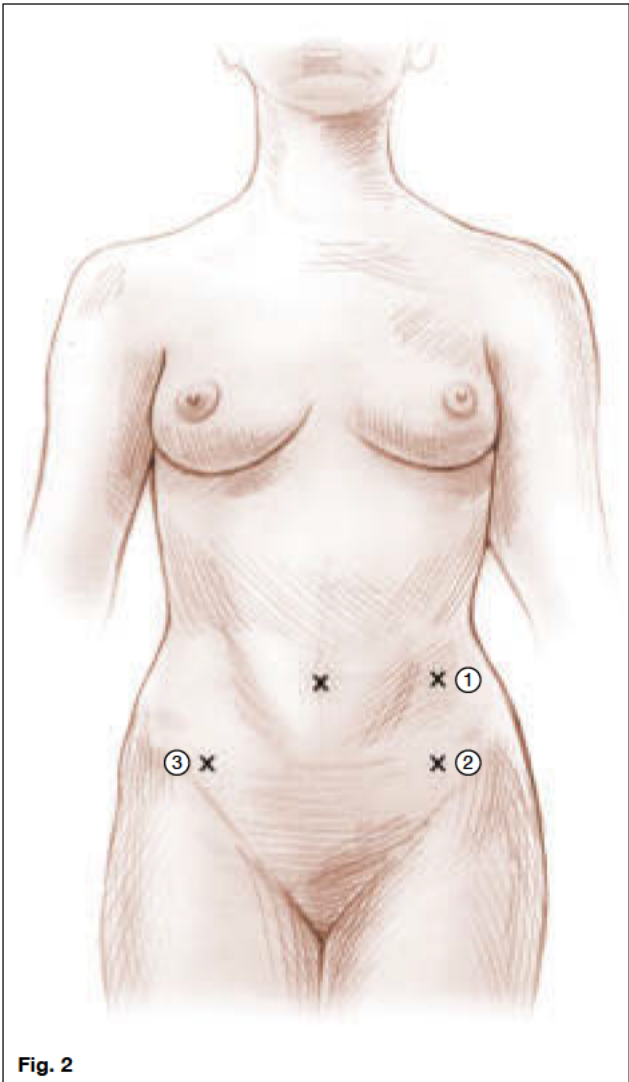


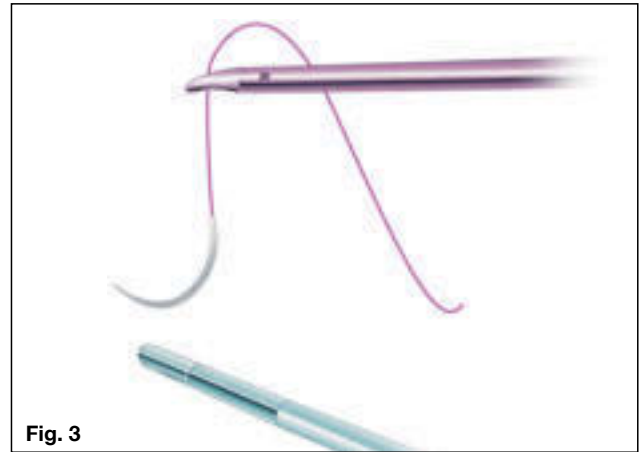Fig. 2

Surgeon standing on patient's left side.


3.3 Suturing


Bringing in the Needle

- I. The needle holder grasps the suture 2 cm from the needle and introduces the needle via the right lower quadrant 10/12 mm port.
- II. The needle should be oriented such that the sharp end is pointing to the left of the patient. This is achieved by gently dragging the needle on the bowel to the right side of the patient.

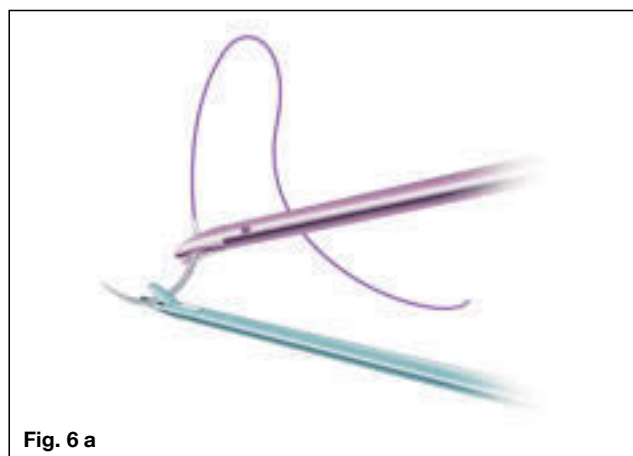


The left-hand grasper now picks up the needle near its mid-position, with the needle tip oriented towards the left.

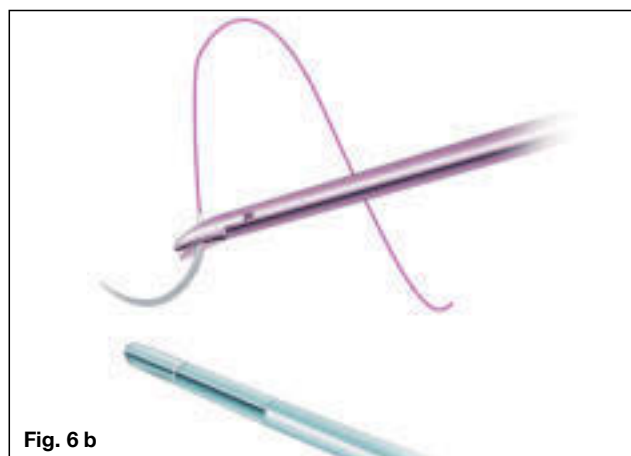




Needle righting: The needle needs to be “righted” before the needle holder can grasp it in the optimal position for driving. This is attained by the needle holder grasping the suture about 2 cm from the swage end of the needle and twisting it upright.



After the needle is righted on the grasper, the needle holder can now grasp the needle at a point two-thirds away from the tip. The angle of the needle to the needle driver shaft is now arranged;



in the case of the jaw with a left curve, the angle is readily achieved by grasping the needle at the tip of the jaw. With a few practice swings, the needle is ready for driving.

3.4 ‘Smiley’ Needle Knot-Tying

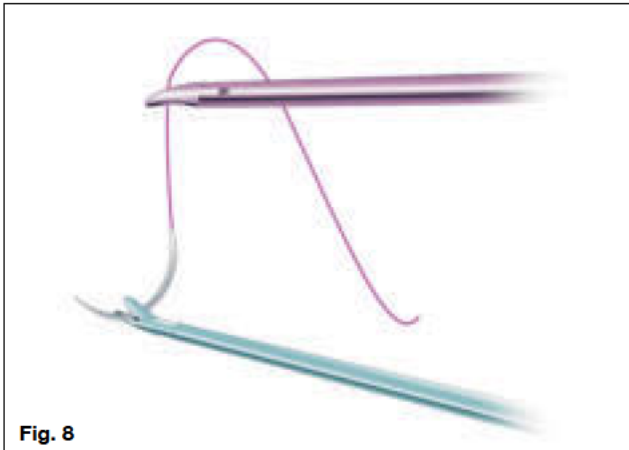This method of intracorporeal suturing can be thought of as a “training wheel” method of achieving intracorporeal knot-tying until one becomes more adept at it. The sequence is shown in **figs. 7-28**. Because the length of suture should not be more than six inches for this method of knot-tying, the ‘smiley’ technique is applicable to single interrupted, cinch or figure-eight knots. With a long suture, the technique becomes too cumbersome.

The ‘Smiley’-Assisted Knot

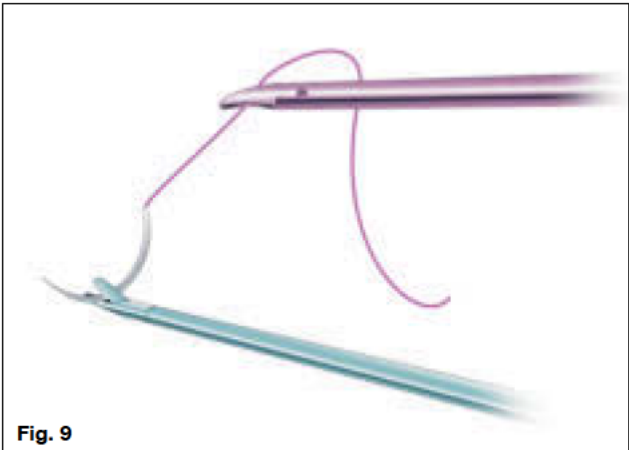
Use of the needle to facilitate throwing intracorporeal knots is a very handy method for beginners who wish to achieve rapid results. The term ‘smiley’ refers to the way the needle is held in an upright position, as indicated in the diagram.




The needle is introduced through the right lower port using the needle holder to grasp the suture 2–3 cm from the swaged end.




After ensuring that the point is facing the patient’s left, the needle is grasped one-third of the way from the tip by the left-hand grasper.



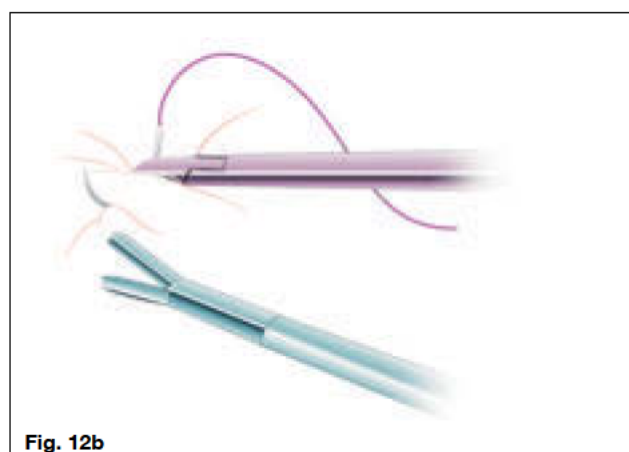

Needle righting now occurs by using the needle holder to gently tug on the suture such that the needle is correctly positioned on the grasper.



The needle holder now grasps the needle one-third from the swaged end.

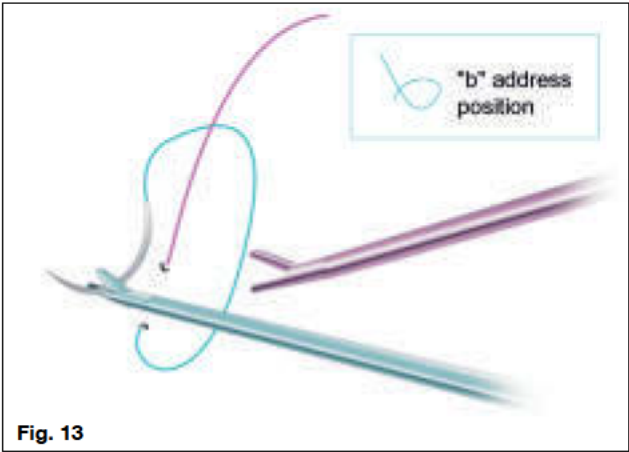


The left-hand grasper releases the needle. When correctly positioned, the needle tip should be between 90° and 135° from the axis shaft.

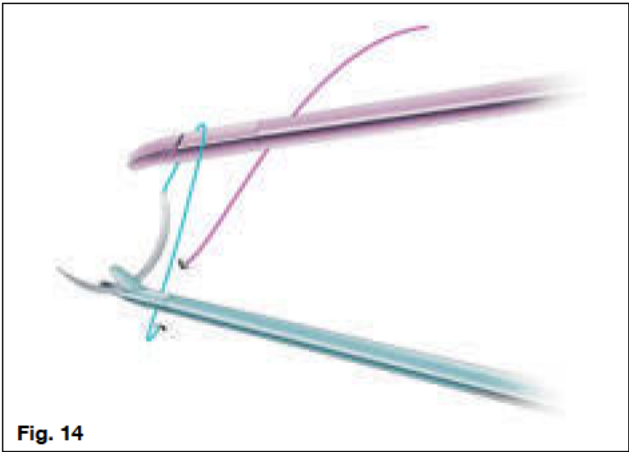


The needle is driven through the tissue. The plane of the needle is the sagittal plane or Vertical Zone™. The left-hand grasper now picks up the end of the needle and the needle exits the wound.


This is the address position prior to knotting.
A figure “b” is created.

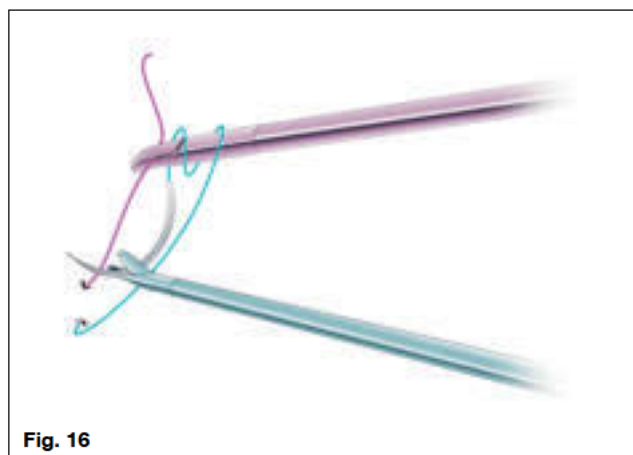


The first clockwise throw is commenced.
The term clockwise and counterclockwise refers to
the tip of the needle holder facing the swaged end
of the needle. Another easy way to think of this is
outside-in rotatory movement.

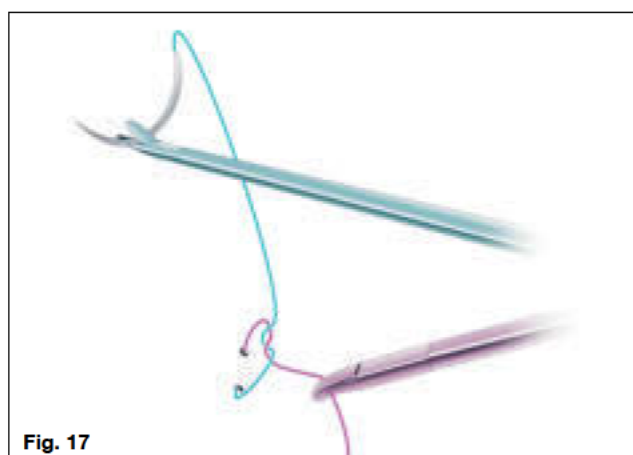


The second clockwise throw is performed.





The upright tail of the suture is conveniently within position and is grasped by the needle holder. This is the reason why the tail is upright in the figure “b” address position.




The left hand now moves caudad while the right hand moves cephalad. This tightens the knot squarely.

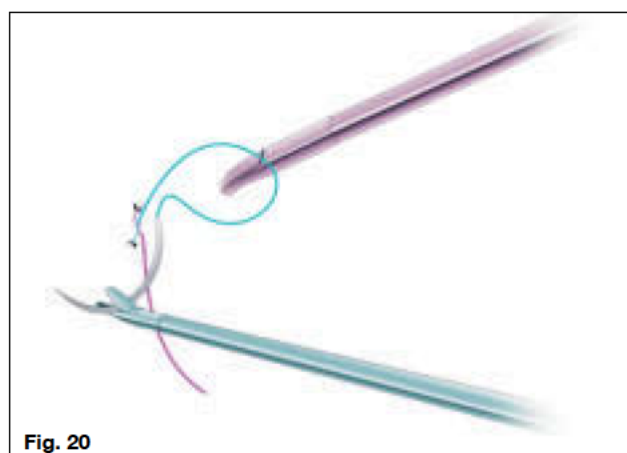


The knot is now tight.


The figure “p” address position is now created. Notice that the tail is now below, due to the last position.




A counterclockwise throw is commenced.



The throw is complete and the needle holder now seeks the tail below.

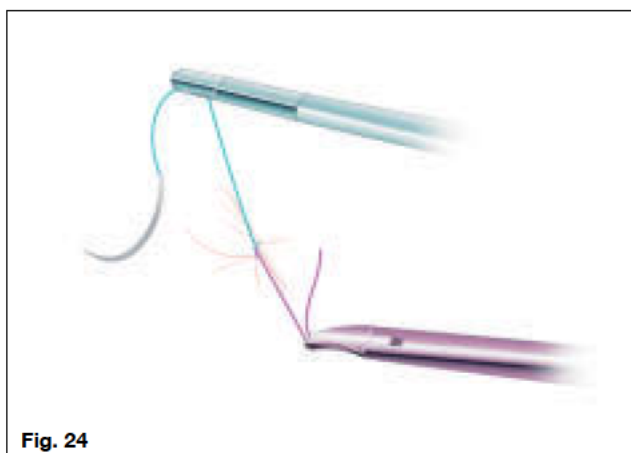




The tail is easily picked up without the loop unraveling.

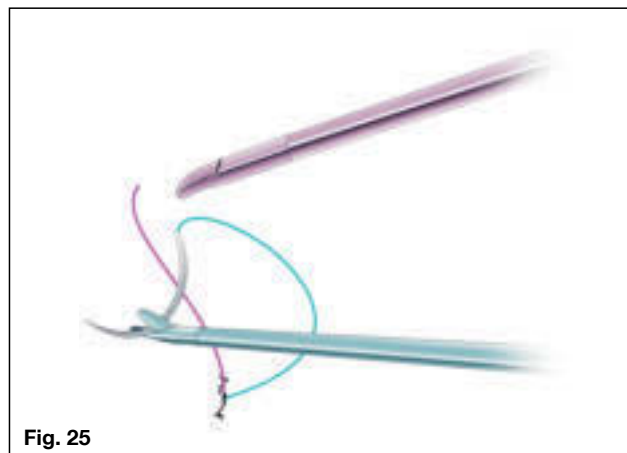


To tighten the knot squarely, the right hand holding the needle holder is now pushed caudad while the left-hand grasper holding the needle is now pulled cephalad.





The needle can now be dropped and the left grasper used to hold the suture closer to the knot to exert more tension.


The needle is picked up by the left grasper in the 'smiley' position and a figure "b" is again formed, this time for a single clockwise throw.



The throw is executed and the needle holder goes very readily towards the available tail.



Again, the tail is pulled cephalad while the left hand with the needle is pushed caudad.



The completed third throw. Depending on the suture material used, between three to six throws may be necessary to secure the knot.

3.5 Expert Knotting

With expert knotting, the surgeon has mastered the ,smiley'-assisted technique and the motions of the clockwise and counterclockwise throw now come automatically. The left hand grasper directly holds the suture instead of the needle. This is where the left curve of the needle holder is absolutely essential. This is more efficient than the ,smiley' technique because the suture can be held closer to the exit wound. Also, after making the throws, tightening of the knot is readily achieved without struggling with the suture length. Furthermore, long sutures for continuous suturing can be used with this technique as the knot throwing is with the terminal part of the suture only. This is almost identical to the ,instrument tie' at open laparotomy, and therefore any open style of knotting can be replicated.




Fig. 29

The needle is driven through tissue in the Vertical Zone™.






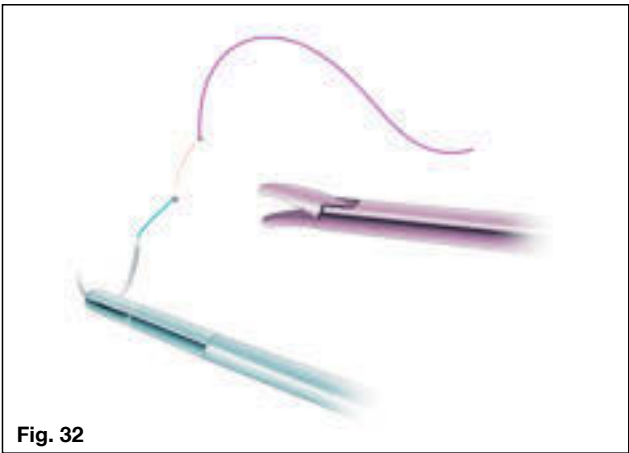
Fig. 30

The needle point exits.

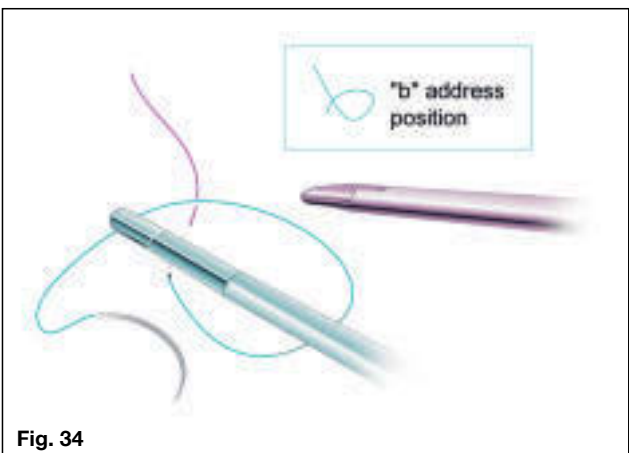
The left-hand grasper picks up the needle point.



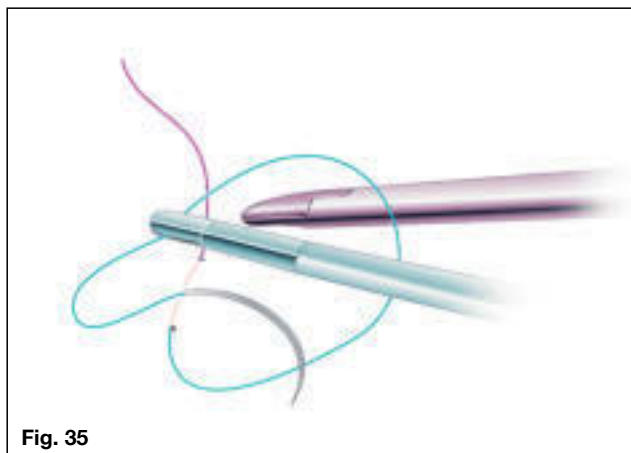
The left-hand grasper pulls the suture through the wound, still holding the needle.



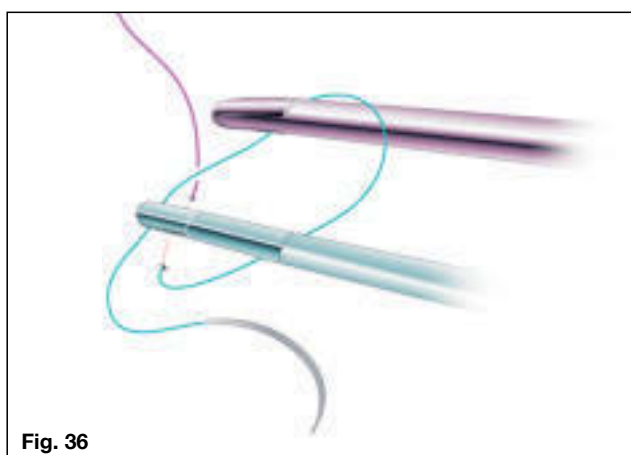
A tail-length of 3 cm is created and this is naturally upright.



Suture is grasped about 6 cm from the tissue and a figure "b" address loop is created.



An outside-in or clockwise throw is commenced.

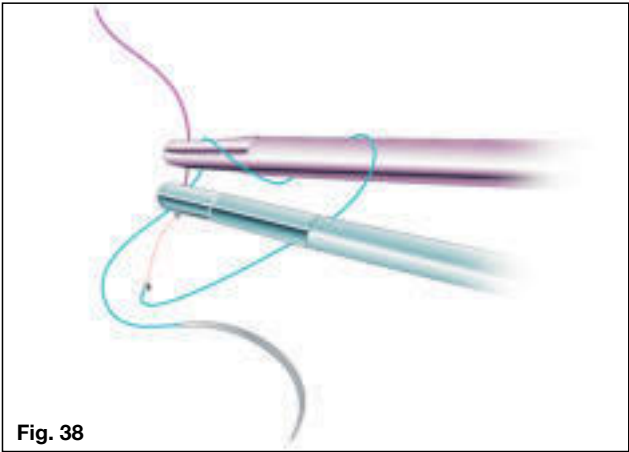


Getting ready to proceed to the second throw.

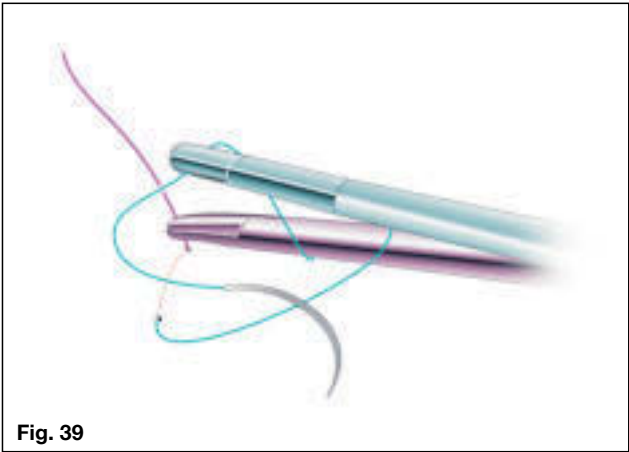


The second throw is commenced.

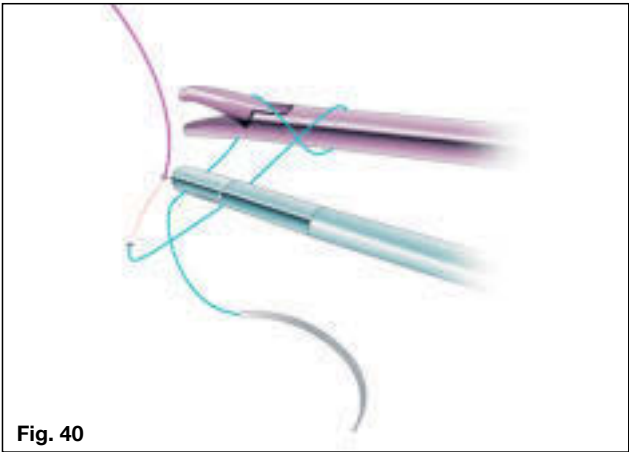
The second throw is complete.




The right-hand needle holder now seeks the upright tail.

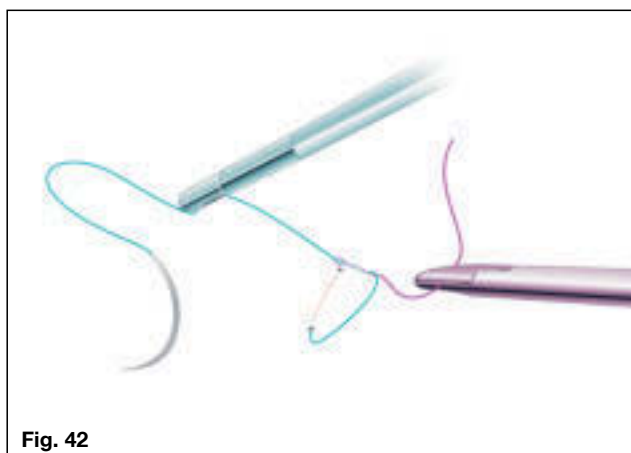


The needle holder approaches the tail.

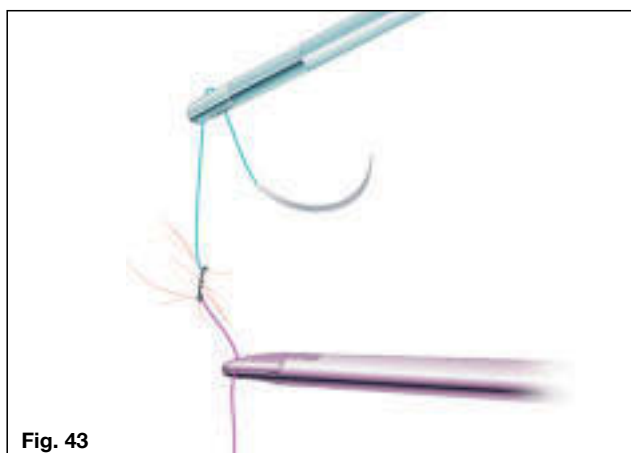




The needle holder picks up the tail.




Very Critical Movement: After picking up the tail, the needle holder moves cephalad and slightly to the right while the left hand moves caudad and slightly to the left.

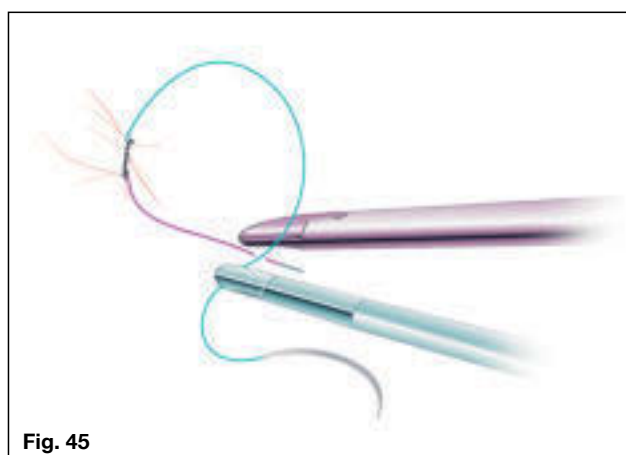

The knot is pulled tight. Note that the right hand with needle holder is below (cephalad) while the left hand holding the needle end of the suture is caudad (above or superior).

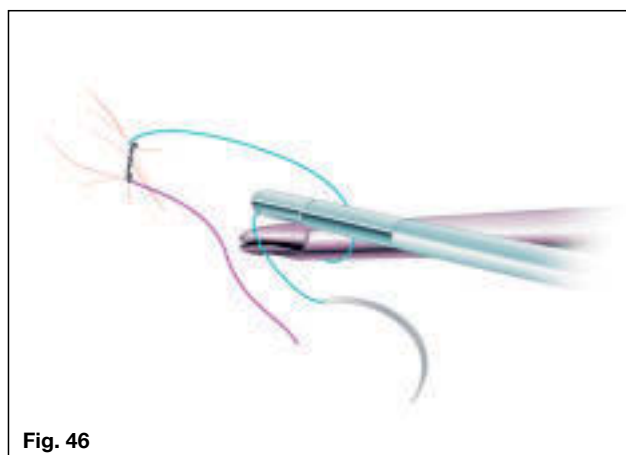
The left hand is now dropped to create a figure “p” address position.

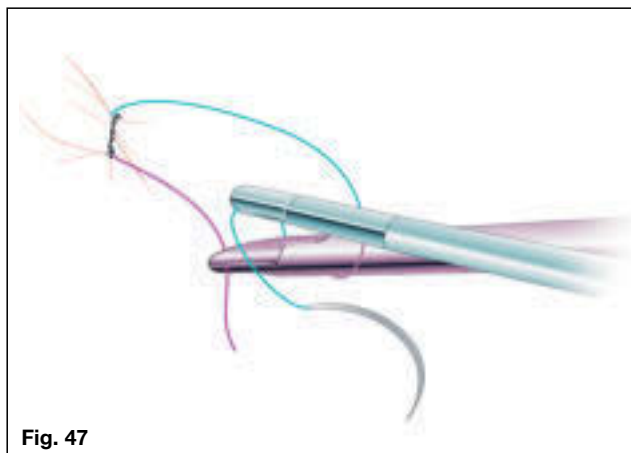


The right-hand needle holder now starts behind the suture to create a counterclockwise loop.



The counterclockwise loop has commenced and the needle holder end very naturally seeks the now inferiorly positioned tail.

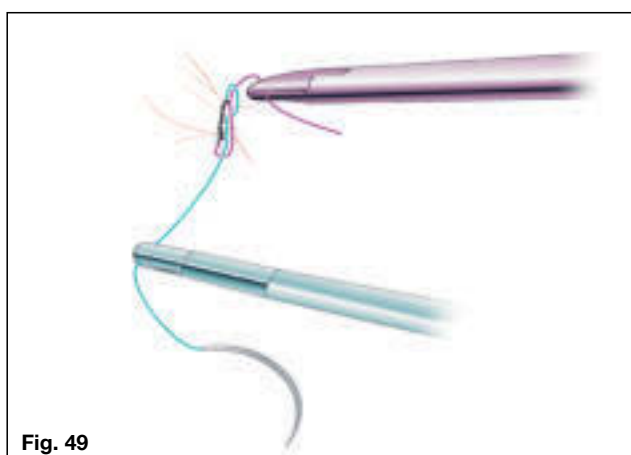




The tail is picked up.

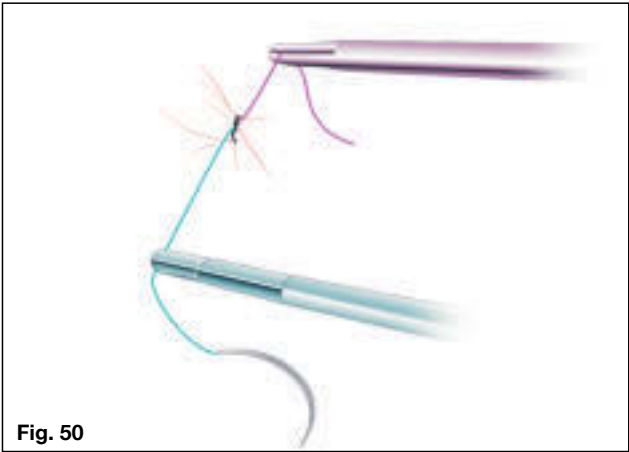


The loop is created.




The right hand with needle holder holding the tail is now moved superior or caudad while the left-hand holding the needle end of the suture is moved inferior or cephalad.

The knot is tightened.



The end of the third throw.



3.6 Cinch Knot

Both convenient and versatile, the cinch knot approximates tissue under tension in the tight confines of laparoscopy. Applications include purse-string suturing, Moschowitz culdoplasty, Burch colposuspension, Nissen fundoplication, uterine artery tying and myomectomy repair, among many others. For apposition of a wound edge under tension (eg. The first stitch after myomectomy when the wound is wide open), the cinch allows effective closure. The cinch also can provide very strong constriction when needed as during uterine artery tying at laparoscopic hysterectomy. Suture material such as Gore-Tex® (W.L. Gore & Associates) and Ethibond® (Ethicon, Inc.), which normally do not stay tight even after a double-throw, benefit from this convertible sliding knot technique. It is vital that the correct part of the suture is pulled or else the knot will become even tighter, rather than ready for sliding. To facilitate this, sutures are color-coded in the following illustrations between entry and exit portions to help identify the correct position for exerting tension.



Fig. 52

The needle is driven through tissue in the Vertical Zone™.






Fig. 53

The needle point exits.

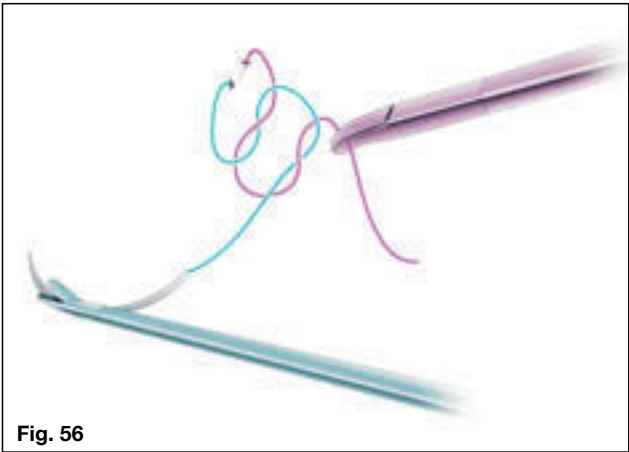
First clockwise throw.




Second counterclockwise throw.

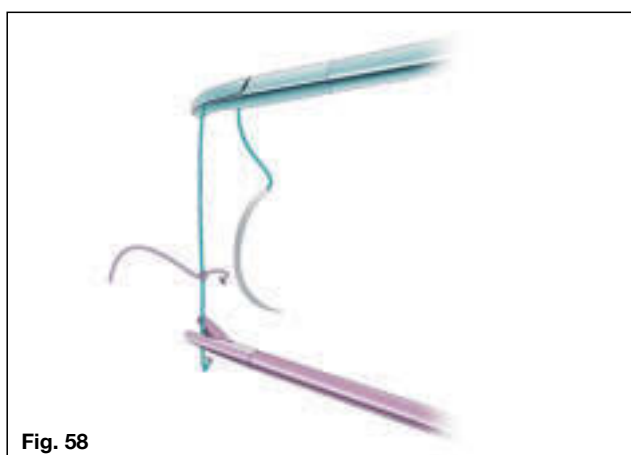

Preparation to tighten knot.





Knot is tightened.

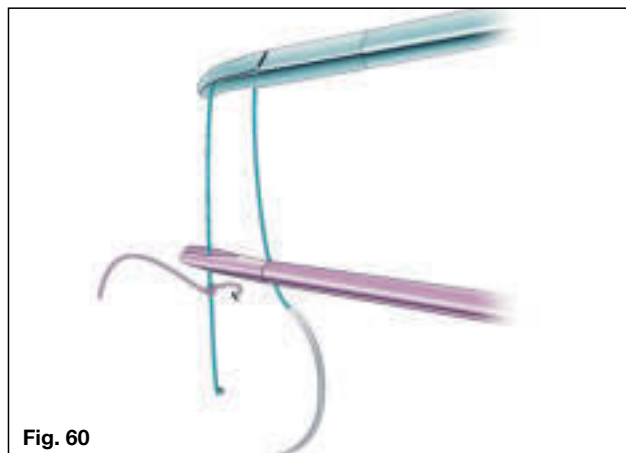


Preparation to pull exit suture.



Tension on suture causes knot to convert.
A “Snap” can be felt when this happens.


Prepare to slide knot down.



Knot is slid down to tighten the “noose”.



Suture ends are pulled apart to re-tighten the knot, converting it back to a non-sliding knot. Several more intracorporeal throws are performed to secure the knot.



3.7 Continuous Suturing

The technique is a composite of multiple needle driving in the vertical plane and tying the knot at the beginning and end. The starting knot can be a cinch or a regular 'expert' knot while the terminal knot can be finished with a loop of the last throw, as at laparotomy. Alternatively, a single interrupted stitch can be thrown at the terminal end and then tied to the terminal end of the continuous suture. We often perform a two-layer continuous suture closure and tie the terminal knot to the original end of the suture. We use this for bladder and bowel repair, and closure after myomectomy and laparoscopic hysterectomy (see **Figs. 67–71**).

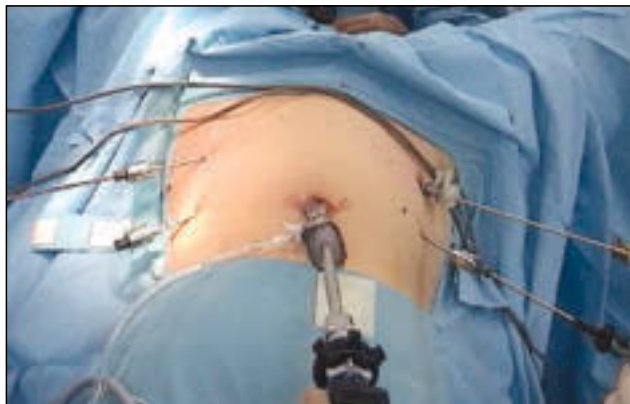4.0 Laparoscopic Microsuturing

Introduction

Microsuturing is a technique that uses 6-0, 7-0 and 8-0 sutures, and places exacting demands on video equipment, instrumentation and operator performance. It is considerably more strenuous than microsurgery by laparotomy. The very highest video resolution is required in order to see an 8-0 suture which is only 45 microns in diameter. We use the TRICAM® SL 3-chip camera system (KARL STORZ) and an 800-line resolution monitor. The *IMAGE 1*® digital camera system (KARL STORZ) brings resolution to an even higher level. The electronic enhancement and auto-iris feature of the digital camera are especially suitable for microsurgery.

All movements for microsurgical knot-tying have been carefully choreographed. After each throw, the needle holder is positioned very closely to the tail it is preparing to grab. Thus, there is no need to “hunt” for the tail in awkward positions. Very much like the strategy used in billiards, the tail is already in position before throwing the first loop. This ensures it can be easily picked up at the completion of that particular throw. The needle holder in the right hand and the grasper in the left hand will move in opposite directions as the clockwise and counterclockwise throws are made, respectively. This is rhythmic and efficient, and rapidly becomes second nature.

Positioning



Port, surgeon and monitor positions are identical to the previous descriptions for macrosuturing. Photos of the external position are shown. Note the differences in instrument size.

4.1 KOH Ultra-Micro Instrumentation

1 Needle Holder

■ Handle

Because of the micro needles used (6-0 to 8-0), minimal needle driving force is needed. Simple finger rotation of the handle, which the axial design facilitates, serves this purpose very well. The continuous ratchet design allows the application of different degrees of pressure, depending on the size of the needle. Additionally, the finger mechanism allows gentle release without the needle accidentally flying off.



■ Needle Holder Jaw

This has a Tungsten carbide insert with very refined micro grooves that allow grasping of the micro needle without deforming it. At the same time, this jaw is able to hold 8-0 sutures for tying without causing rupture.



2 Ultramicro Graspers

■ Ultramicro-1 Grasper

This has a tip diameter of 500 microns and is used for holding serosa and for 6-0 suturing.



■ Ultramicro-2 Grasper

This has a tip diameter of 250 microns and is used for holding tubal muscularis as well as assisting with 7-0 and 8-0 suturing.



Tips:

The tips of these graspers are sandblasted to prevent glare from the laparoscope. The micro serrations hold tissue firmly but without trauma. The jaws are also capable of intracorporeal knot tying without rupturing 8-0 suture. To facilitate intracorporeal knot tying, a left and right curve grasper is available in the series. The handles come in slightly larger and smaller sizes to suit various preferences. The shaft can now rotate, allowing for greater versatility in the application of the jaws.

3 Scissors

The micro suture cutting scissors have a very sharp point to allow precise knot cutting.



The blunted nose dissecting scissors are used for microdissection and cutting.

4 Pitressin Needle

This fine needle is used for injection of 1:40 dilution Pitressin® (vasopressin) into the tubal serosa. This is also used for Pitressin injection prior to myomectomy. Because of its fine needle tip, it is not suitable for cyst aspiration.

**5 Chromopertubator Sizer**


The markings represent a diameter of 1, 2 and 3 mm, respectively. This allows the diameter of the tubal lumen to be measured to create a similar sized opening prior to anastomosis. It is also used for chromoprotubation of the distal tube.

**6 Guillotine**

This is convenient for transecting the fallopian tube or ureter for anastomosis.

**7 Micro Needle Electrode**

This has a fine 150 micron tip and is used for fine dissection, cutting and micro homeostasis. The current setting should be at 15 watts coagulation and 20 watts pure cut.



KOH Ultramicro Instrumentation

4.2 Magnification and Resolution

Laparoscopic magnification up to 30x can be achieved with a high-resolution (800 lines or greater) monitor and three-chip video camera. This is more than adequate for microsurgical anastomosis. The current availability of the digital camera and high-resolution monitor will make resolution even more spectacular.

4.3 Microsutures

Regular micro sutures for laparotomy can be used. We use Prolene® (Ethicon, Inc.) 7/0, 8/0 with a BV 175-6 titanium needle for tubal anastomosis because of their tensile strength and sharpness.

Instrumentation

Specially designed KARL STORZ Ultramicro Instrumentation (see complete listing under **Basic Set for Laparoscopic Suturing**, page 58) is used for micro dissection and microsuturing. The jaws of all the graspers and needle holders are designed so as to be atraumatic on tural tissue and 8-0 sutures. The tip diameters of the graspers are the smallest of any laparoscopic instrumentation.

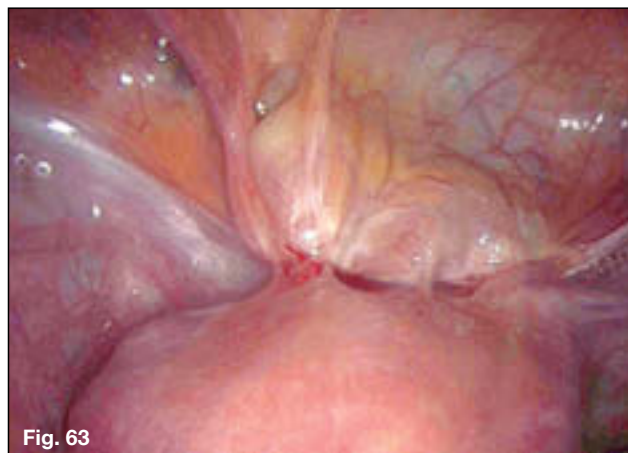Operator Performance

Advanced laparoscopic skills as well as suturing ability are essential for performing microsurgery.

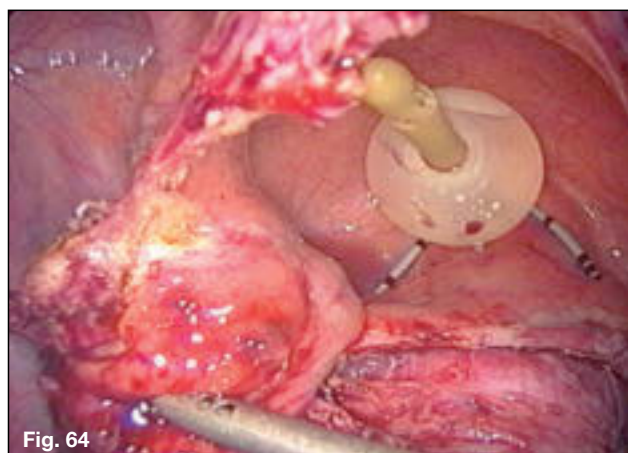
5.0 Vertical Zone™ Suturing Techniques in Advanced Laparoscopic Surgery

5.1 Partial Cystectomy for Infiltrative Endometriosis

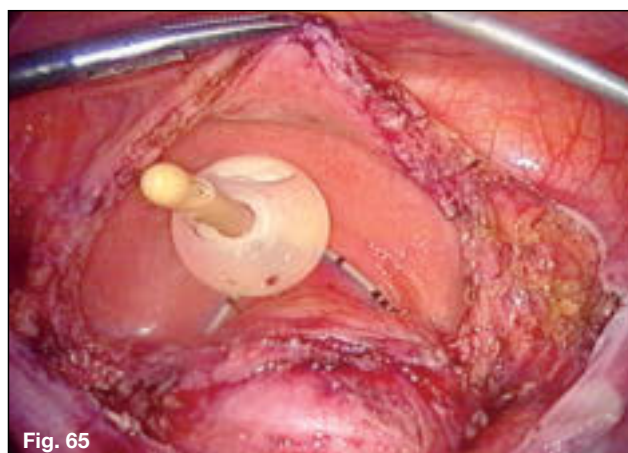
Laparoscopic view of the scarring over the bladder endometriosis.

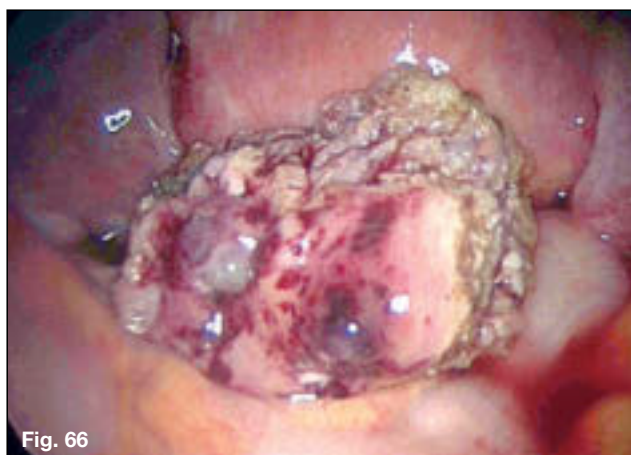

Partial cystectomy. The mucosal infiltration of the endometriosis is seen.

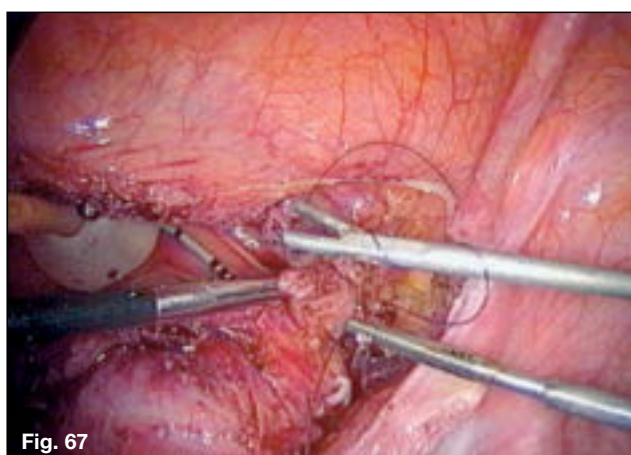

Partial cystectomy completed. Foley and ureteral catheters are seen at the bladder tricone.

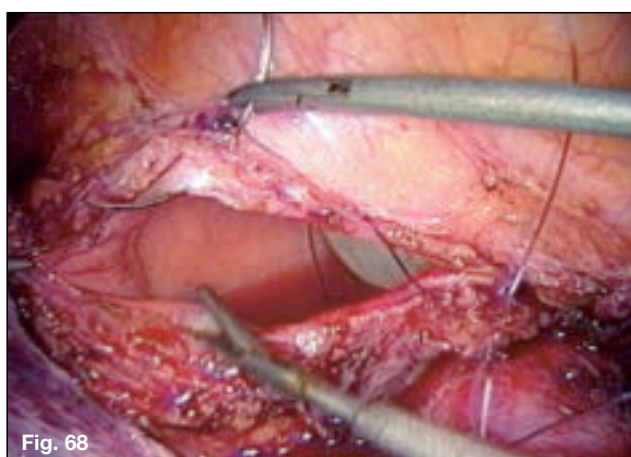




Resected specimen from bladder-mucosal side.

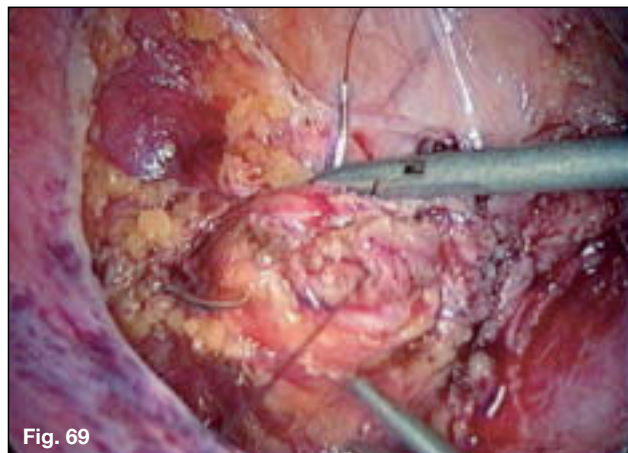


Start of continuous suturing using 3-0 monocryl and 3 mm KOH ultramicro needle holder and KOH ultramicro 1 grasper.

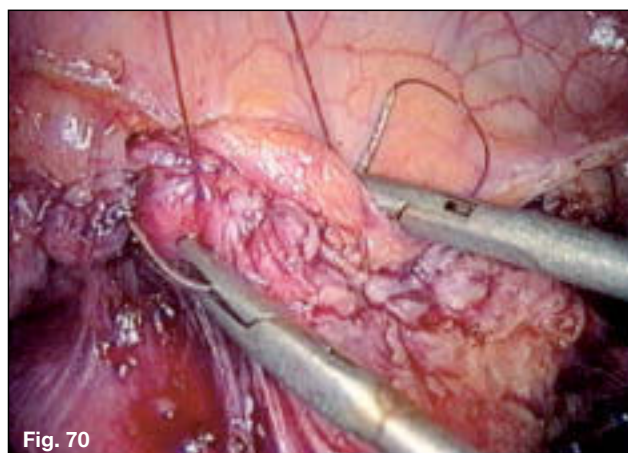


Further continuous suturing towards the left edge.

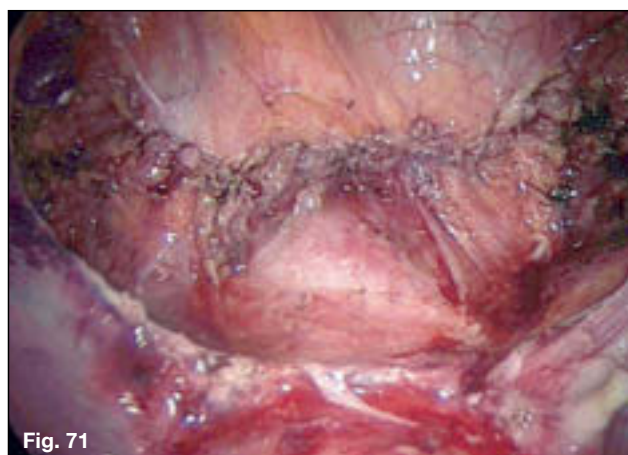
Start of second layer using the same suture.

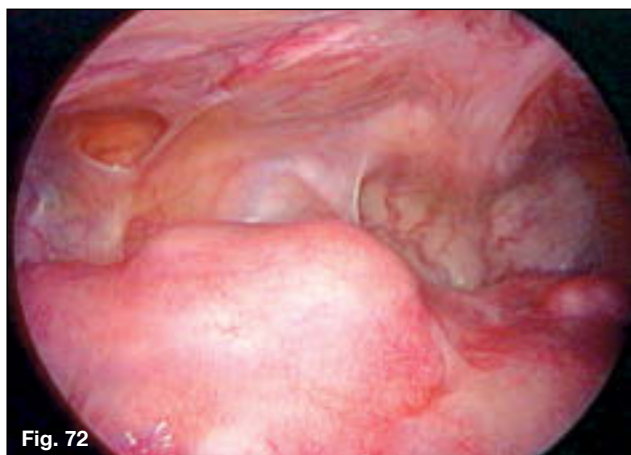

Completion of the second layer back to the original start point where it will be tied to the end of the suture.



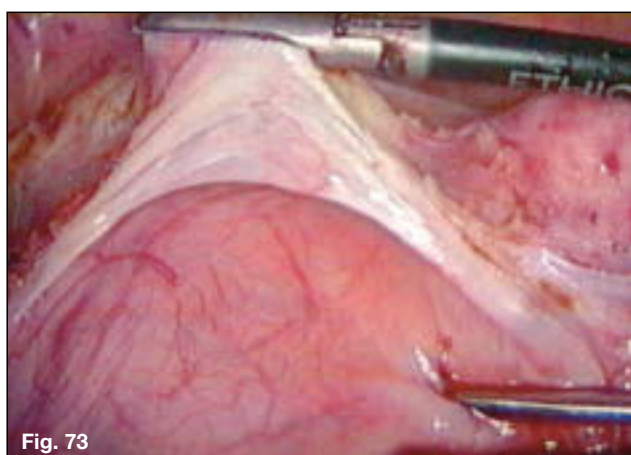
Completed bladder repair in two layers continuously using one suture and ultramicro instrumentation.



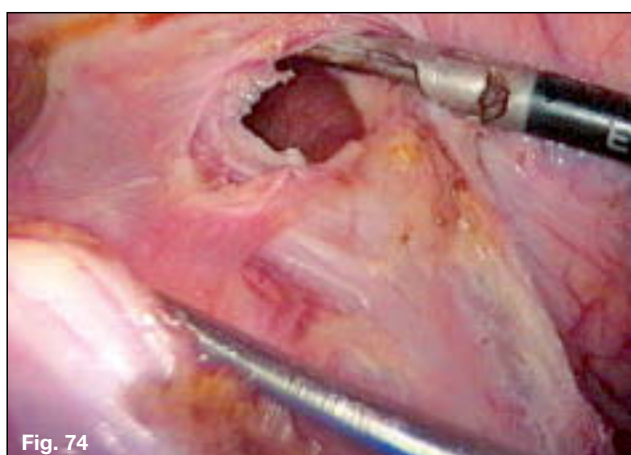


5.2 Repair of Bladder Damage at Total Laparoscopic Hysterectomy

Patient had multiple myomectomy previously with subsequent bladder scarring over uterus.

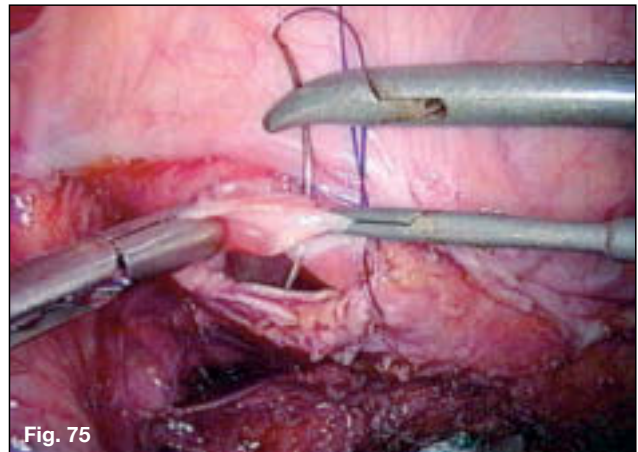


Ultrasonic scissors are used to divide bladder flap.

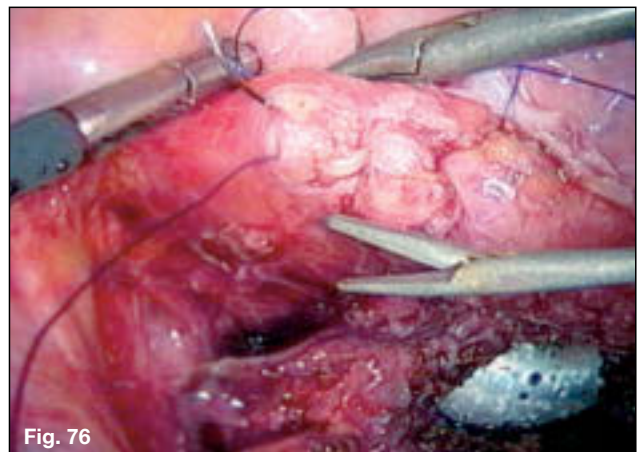


Cystotomy is identified.

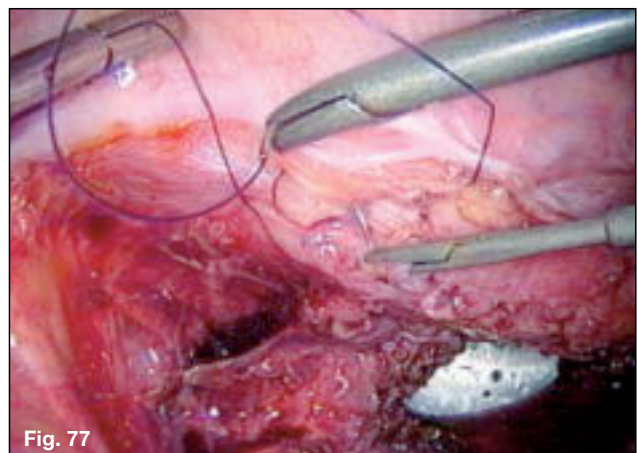
First layer continuous suture using 3-0 Monocryl KOH macro needle holder and KOH ultramicro 1 grasper.



Completion of first layer and start of second layer.



Second layer imbricating the first.



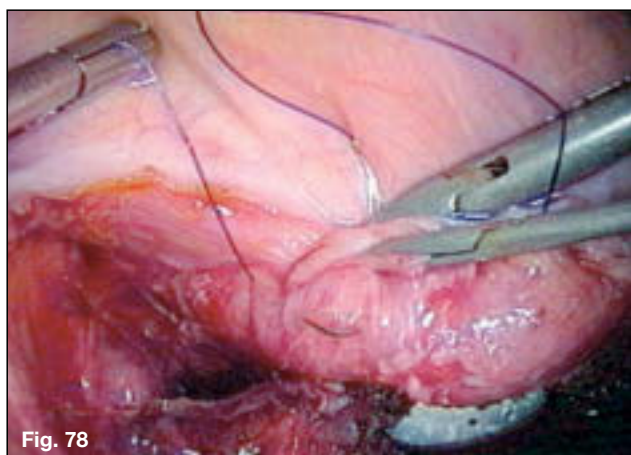


Fig. 78

Last stitch of second layer.

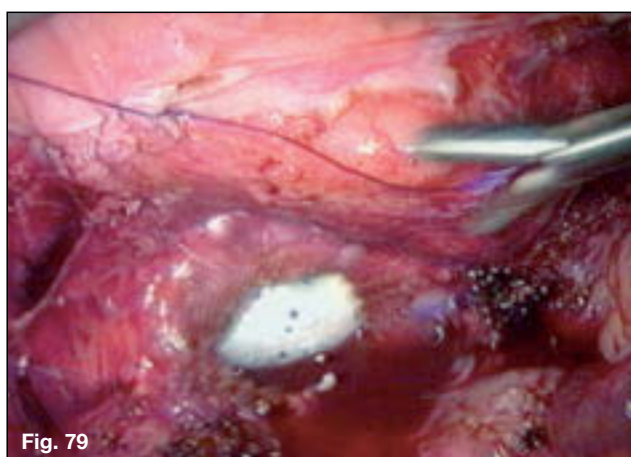
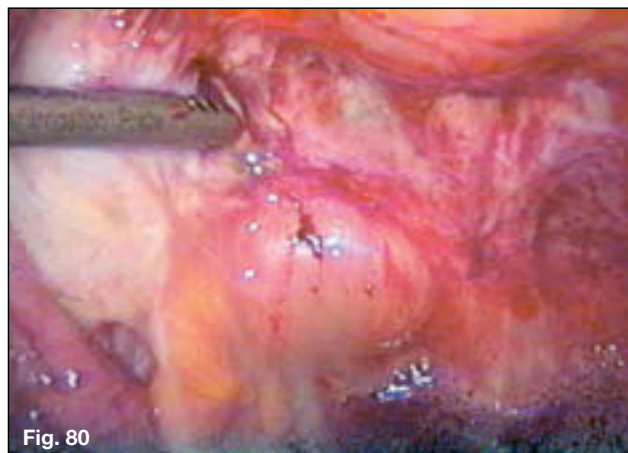

Fig. 79

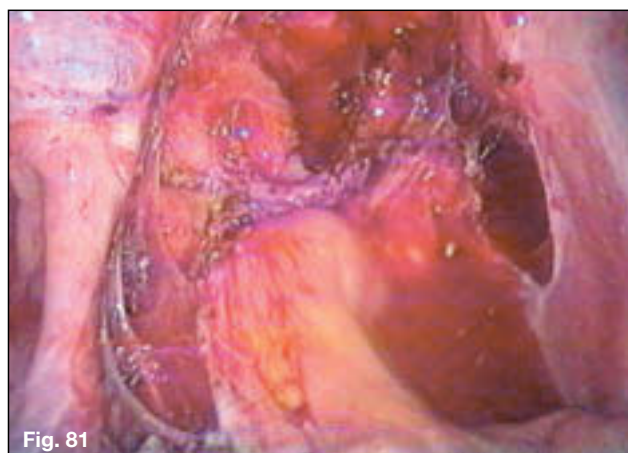Bladder repair is completed. Open vaginal vault of total laparoscopic hysterectomy prior to repair with balloon in vagina is seen below repaired bladder.

5.3 Full Thickness Disc Resection of Rectal Endometriosis Involving Muscle and Mucosa

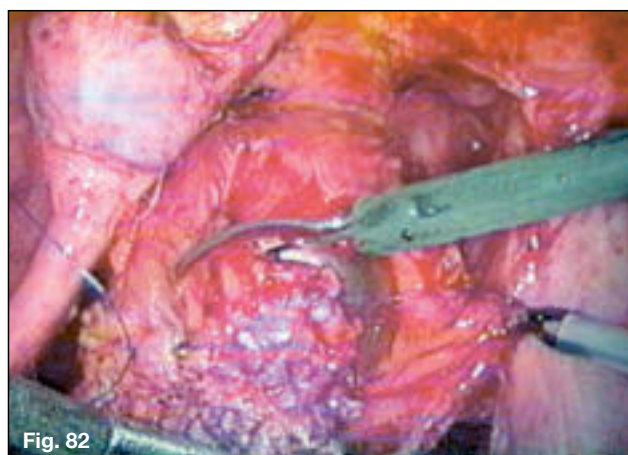
Severe rectovaginal endometriosis with cul-de-sac obliteration.

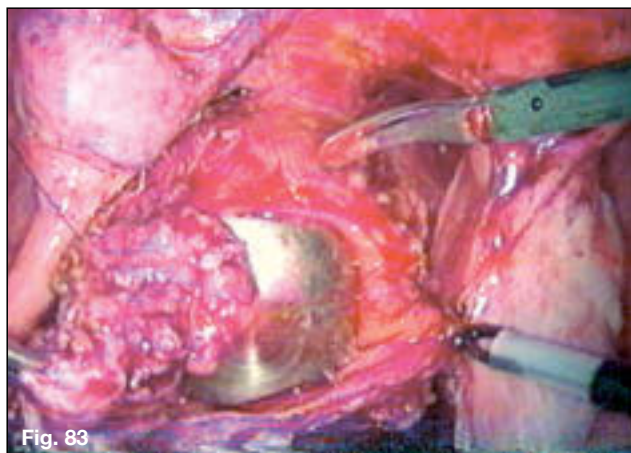


Rectovaginal space dissected 4 cm beyond the rectal lesion to normal rectal tissue.

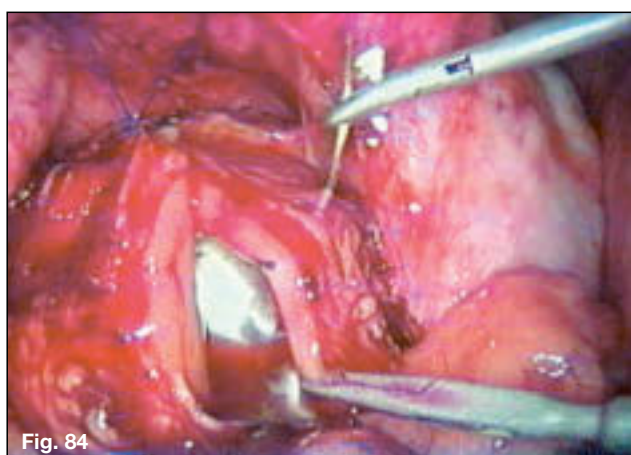


Excision of rectal endometriosis full thickness.

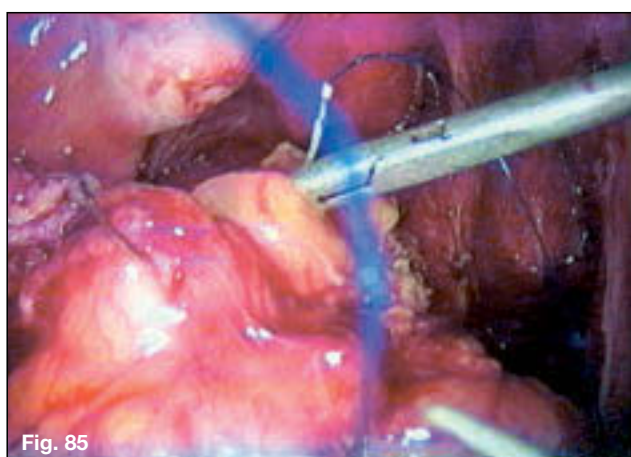




EEA sizer in rectum to support rectum during anterior disc excision.

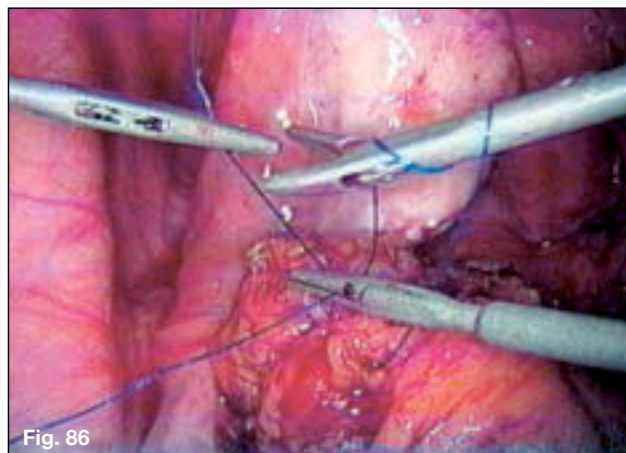


First layer closure of muscularis and mucosa using 3-0 prolene on an SH needle. KOH ultra micro needle holder and micro 1 grasper used.

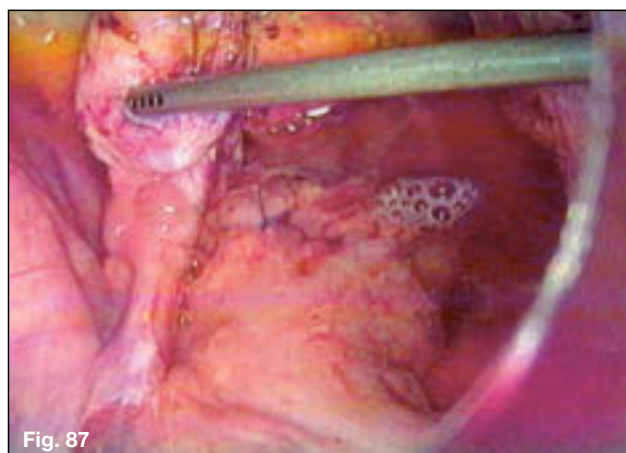


Second layer using same suture is performed towards the original knot on the left.

Second layer completed and suture tied to original end of suture. Clockwise double-throw intracorporeal knot being performed.



Completed two-layer anterior rectal repair with single 3-0 continuous Prolene. Underwater test for air leakage. The left ovary is being pushed laterally by the irrigator.



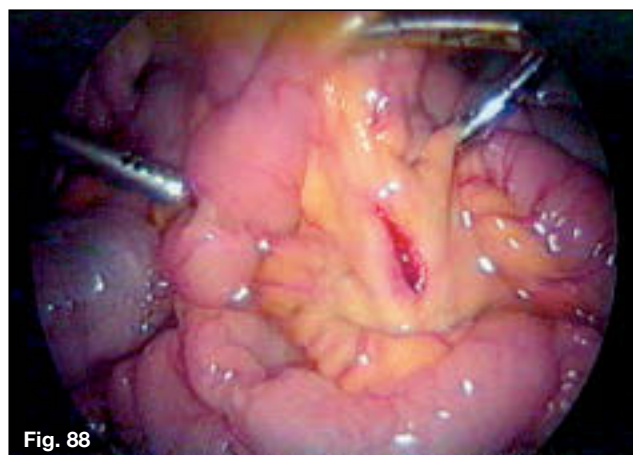


Fig. 88

5.4 Repair of through-and-through Trocar Injury of Ileum using 6-0 Prolene BV-1 Needle and KOH Ultramicro Instrumentation

Iliac mesentery perforated by primary trocar.

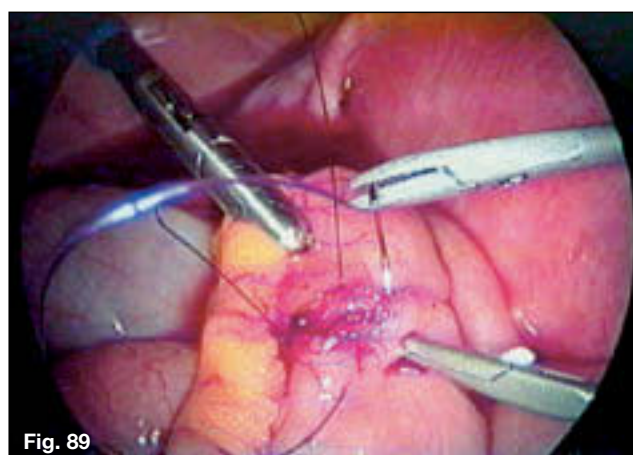

Fig. 89

First layer is completed.

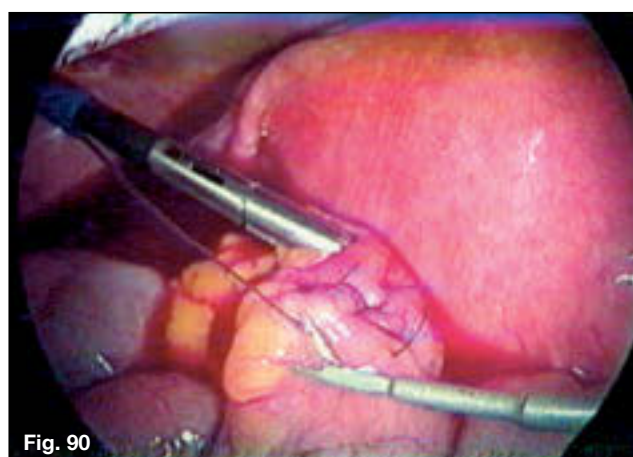
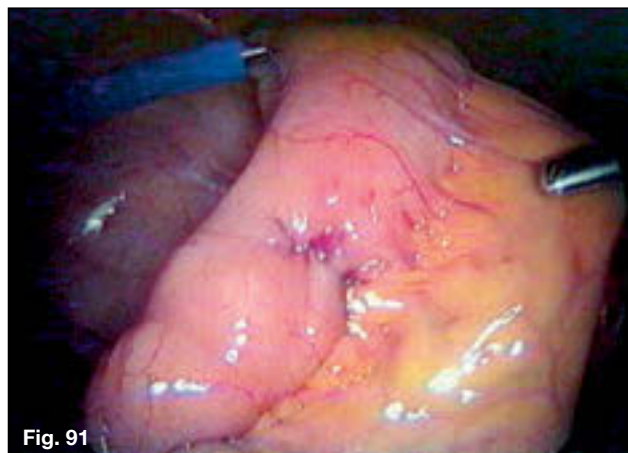

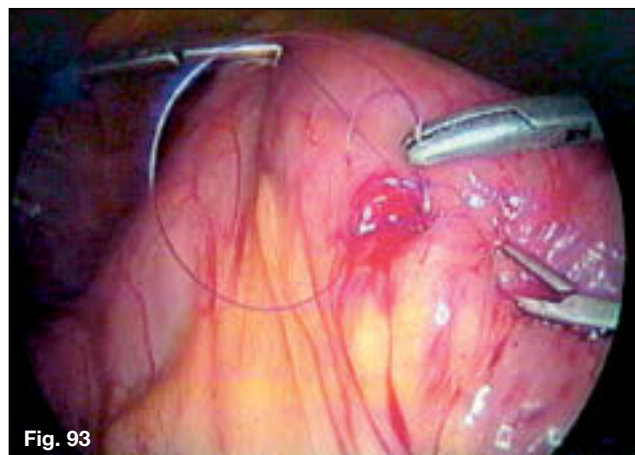
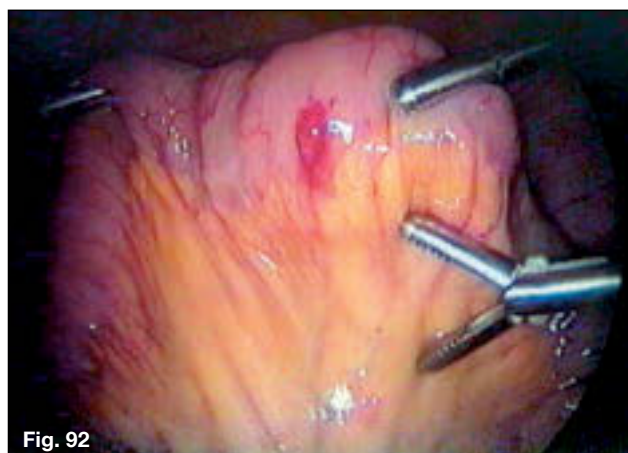
Fig. 90

Second layer is performed.

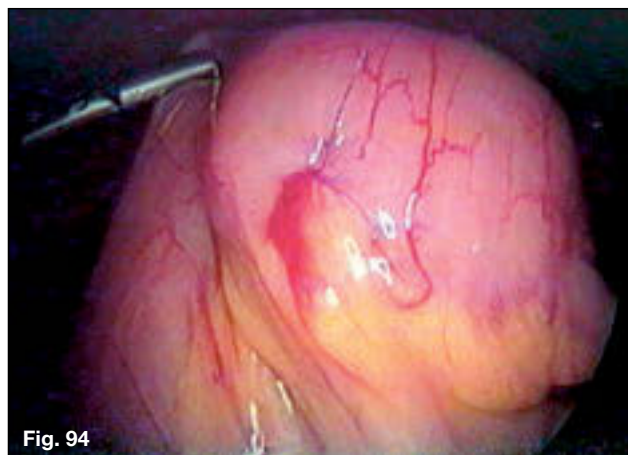End of repair.



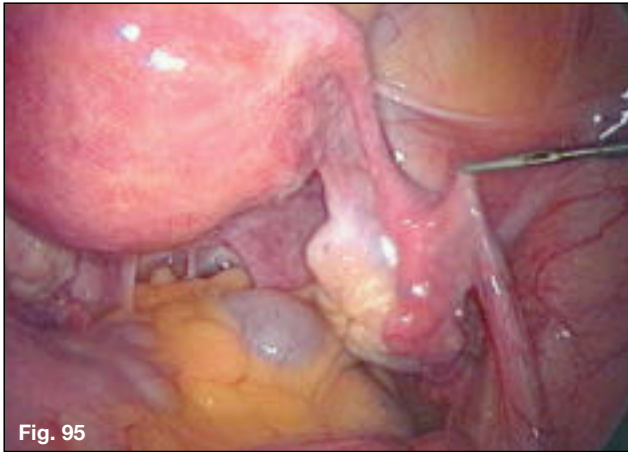
Trocar has perforated posterior wall as well.



Posterior wall repaired with figure-of-eight 6-0 Prolene using KOH ultramicro instrumentation.



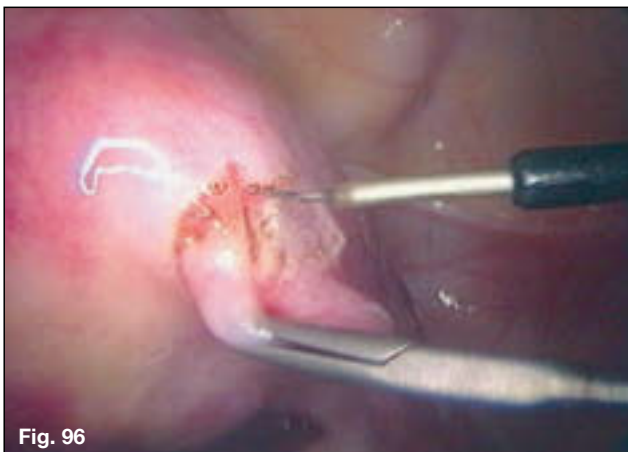Completed posterior wall repair.



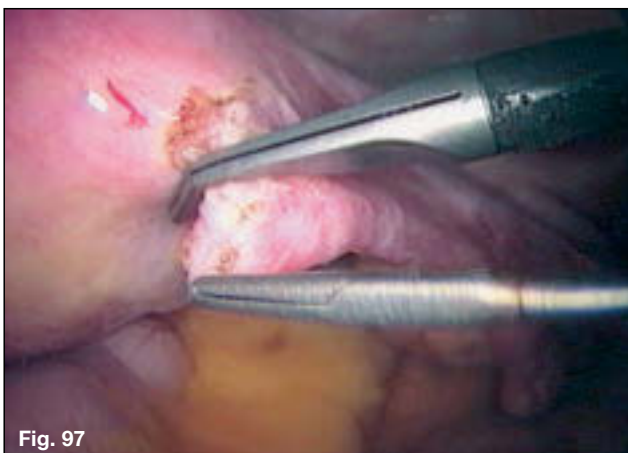
5.5 Tubocornual Anastomosis Secondary to Fibrosis

Right tubocornual anastomosis performed using 8-0 prolene BV175-6 titanium needle and KOH ultramicro instruments

Cornual and isthmic blockage secondary to fibrosis.

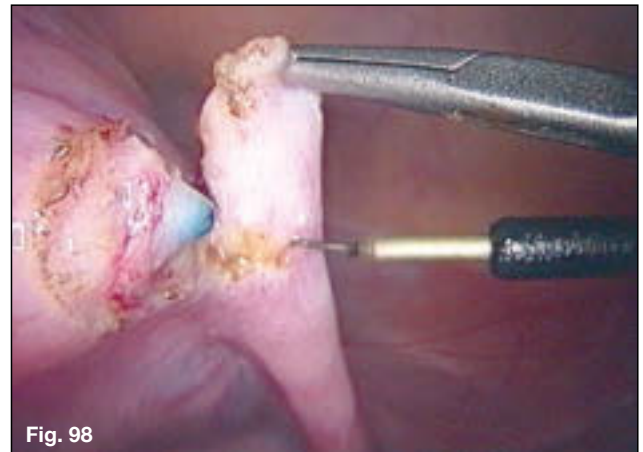


Micro needle electrode is used.

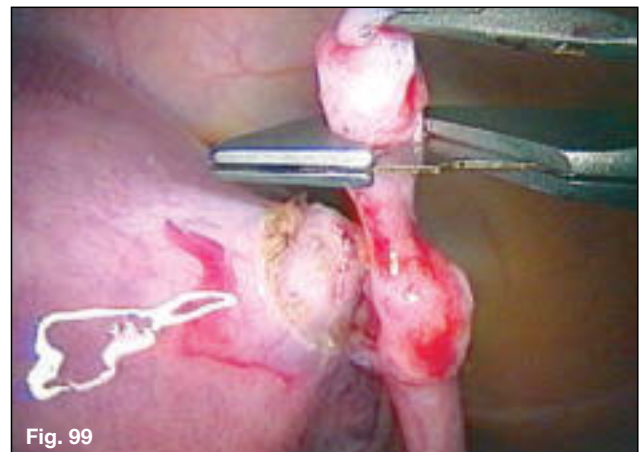

A guillotine is used to transect the cornual fibrosis.

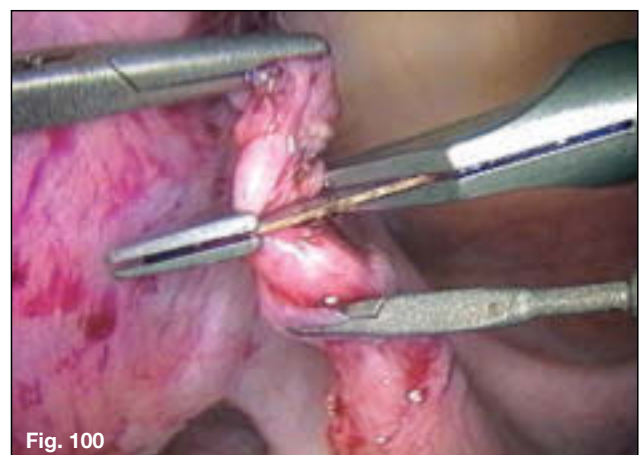
The isthmus of the tube is transected.

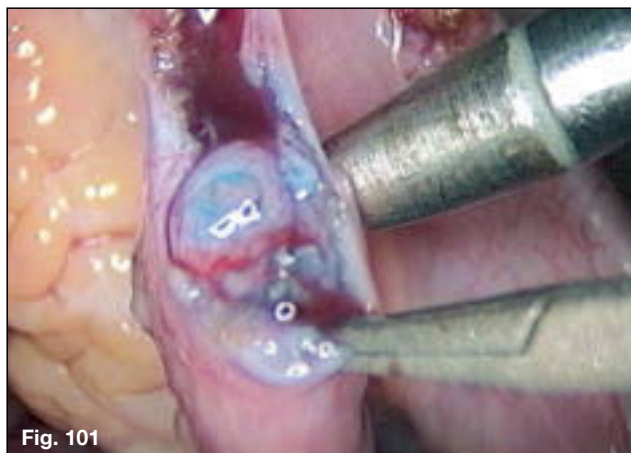


Further transections of the isthmus are performed.

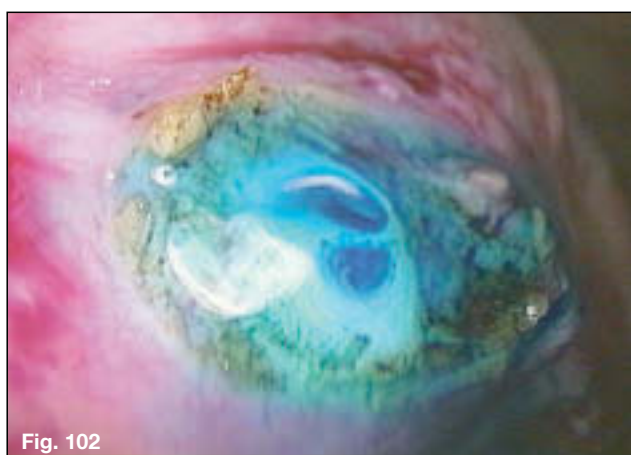


The final transection reveals a lumen.

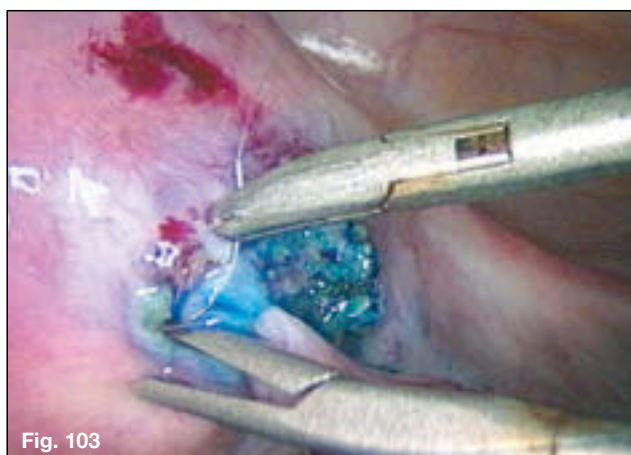



Normal lumen and muscularis of mid-fallopian tube.

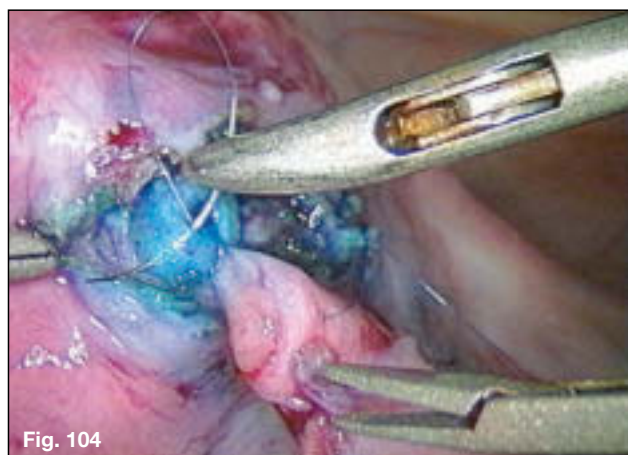


Patency and normal interstitial tube revealed after serial cuts into the uterine cornua.



A suture is placed at the 12 o'clock position. The 6 o'clock suture has been tied.

An additional suture is placed at the 9 o'clock position.



The completed right tubocornual anastomosis.

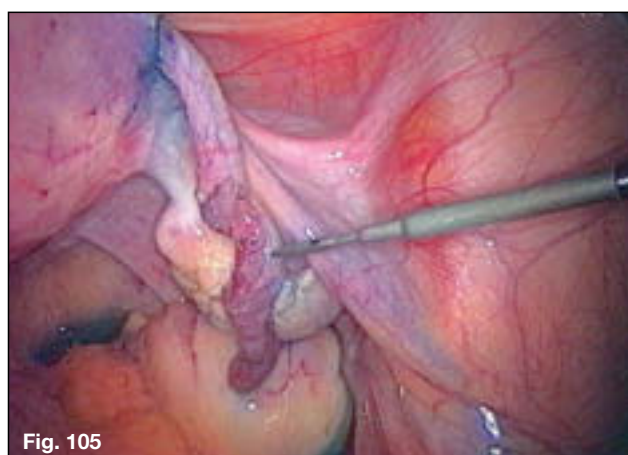

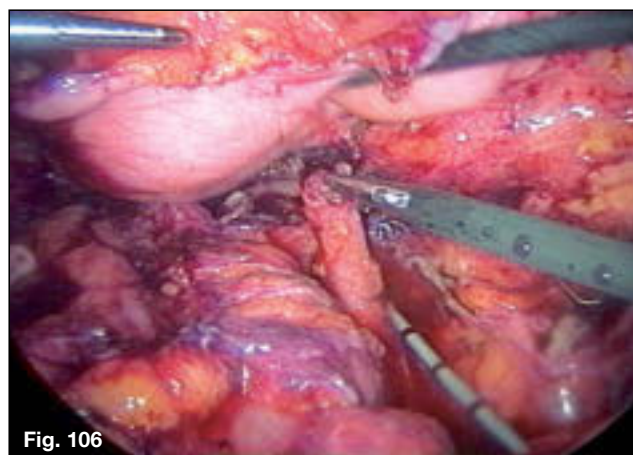


Fig. 106

5.6 Laparoscopic Cystoureterostomy Secondary to Ureteral Damage After Hysterectomy

The free end of the ureter is seen and the bladder is released to create a tension-free anastomosis.

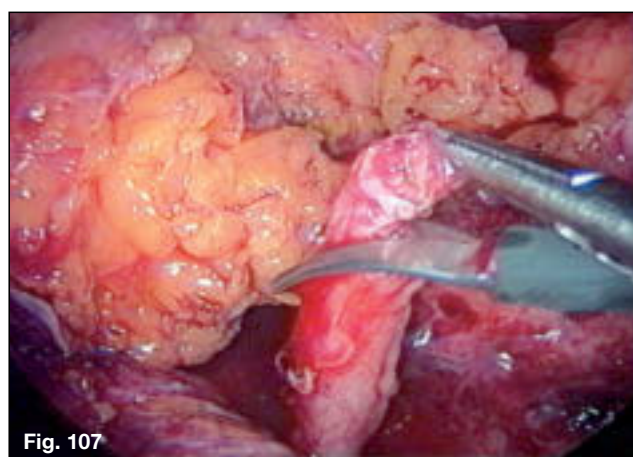


Fig. 107

An oblique incision is made in the terminal end of the ureter to obtain a fresh edge.

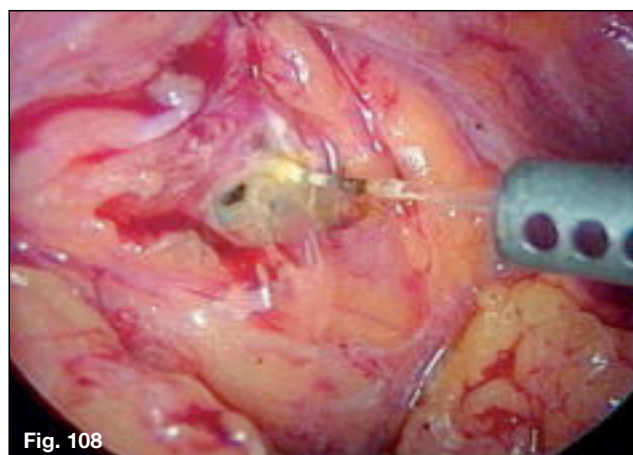
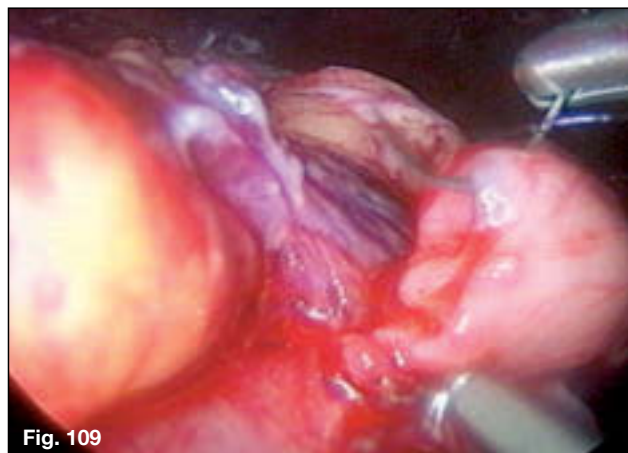


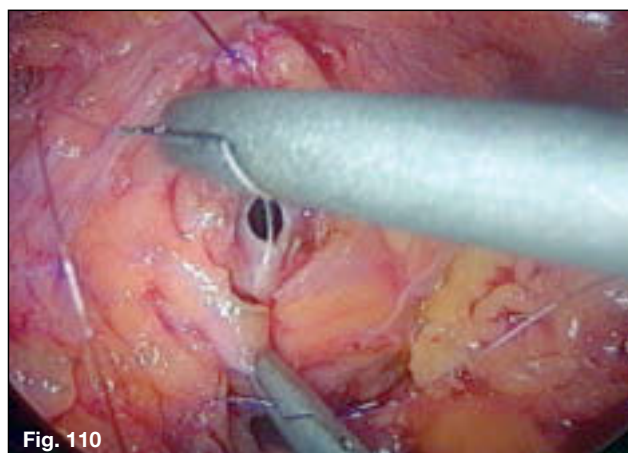
Fig. 108

An incision is made into the bladder using the KTP laser to create a 4 mm opening.

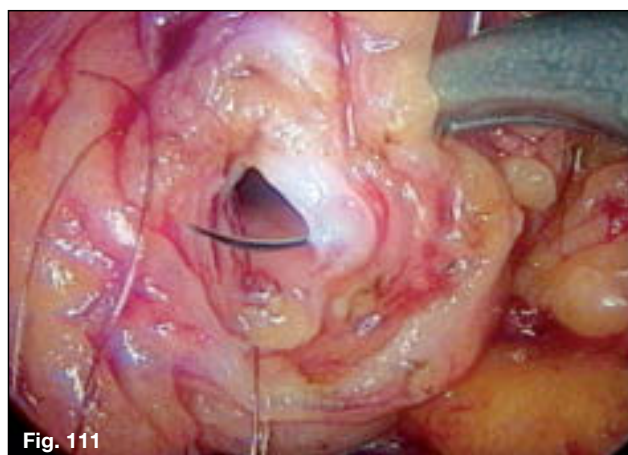
The first stitch is inserted into the ureter at 6 o'clock using 5-0 monocryl.

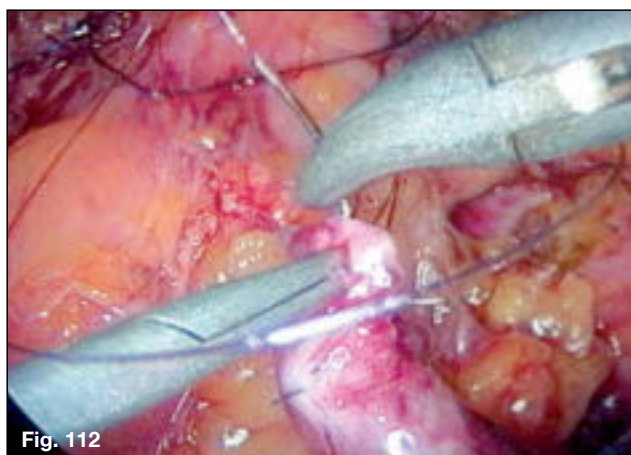


The same suture is inserted through the bladder mucosa and muscularis at 6 o'clock. This is tied with a cinch knot and left long.

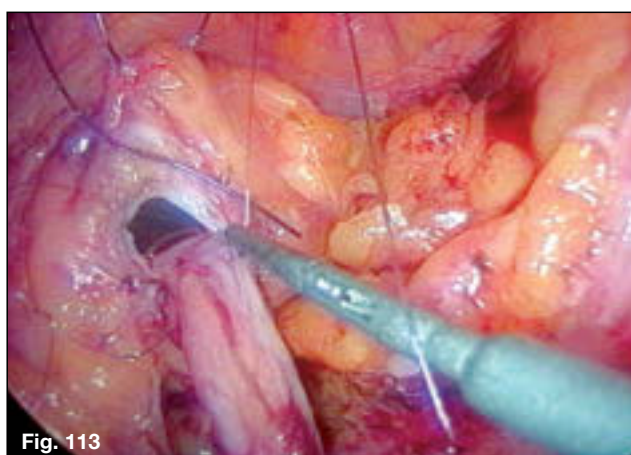


The second suture is placed at 3 o'clock in the bladder.

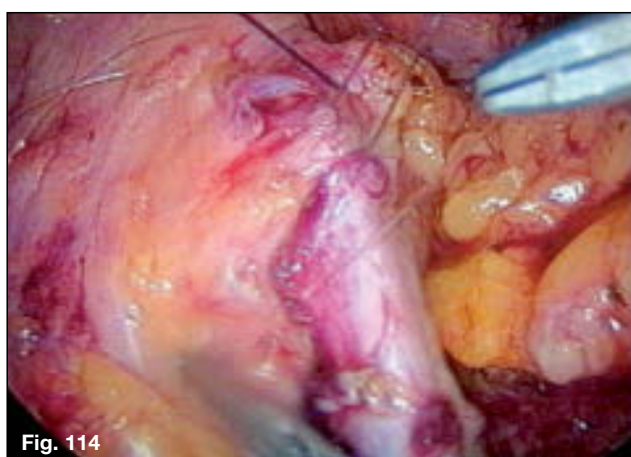




The suture is placed at 3 o'clock into the ureter.

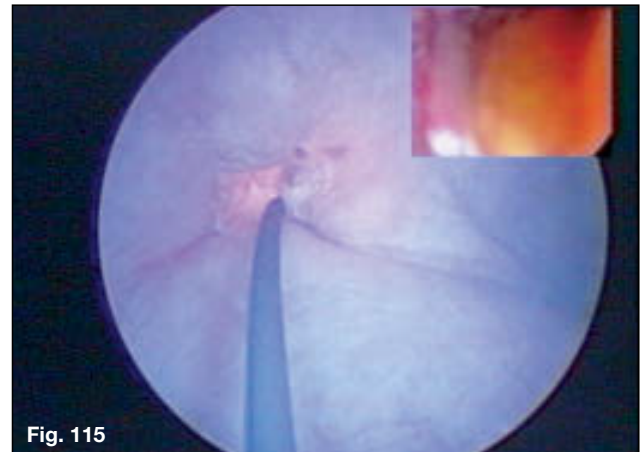


The 3 o'clock suture is tied after the 6 o'clock has been tightened.

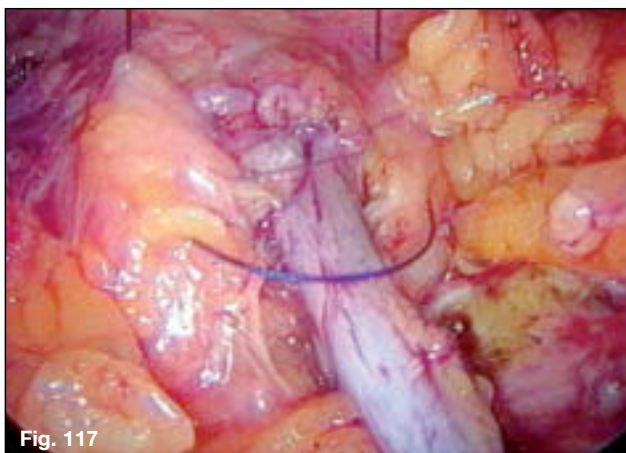
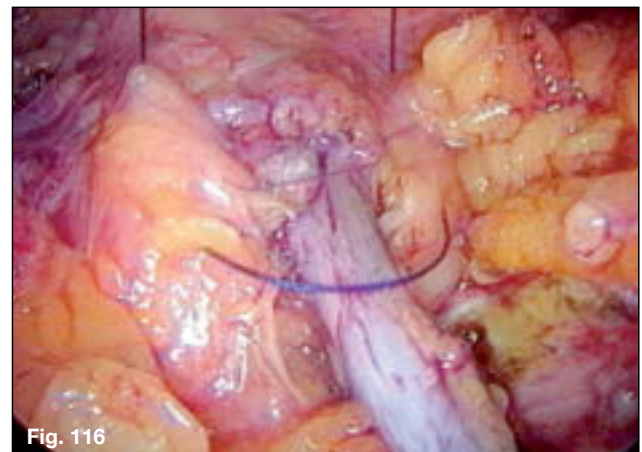


After placing the 9 o'clock and 12 o'clock sutures, they are both tied.

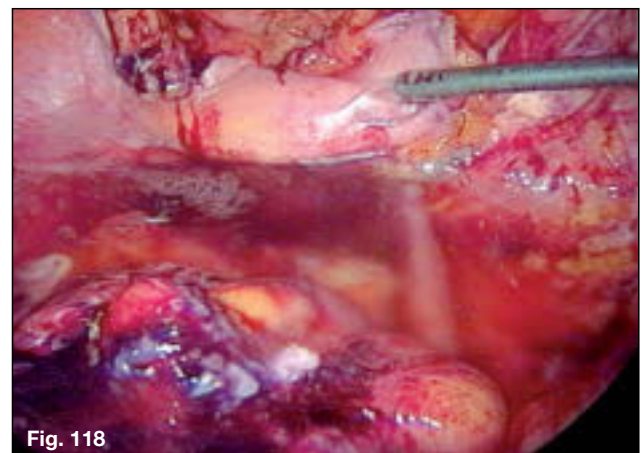
A cystoscopy is performed to confirm good anastomosis and patency.



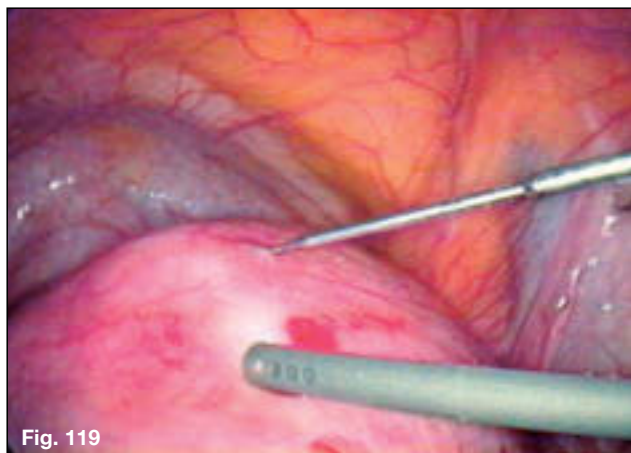
A tunnel is created with a mattress suture of the bladder muscle over the ureter.



A completed ureteric neotunnel.

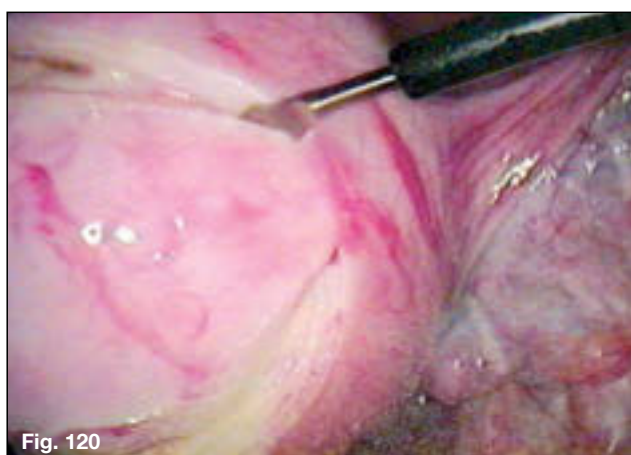

Completed ureteroneocystostomy.

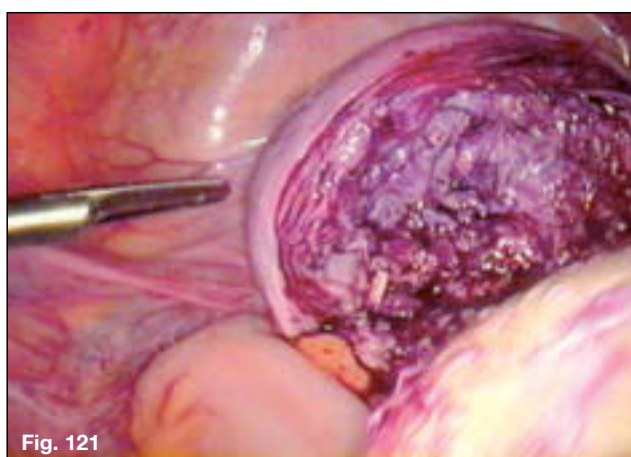


5.7 Myomectomy – Anterior Intramural Fibroid Measuring 7 cm

Diluted 1/50 Pitressin is injected through the KOH ultramicro needle 3 mm.

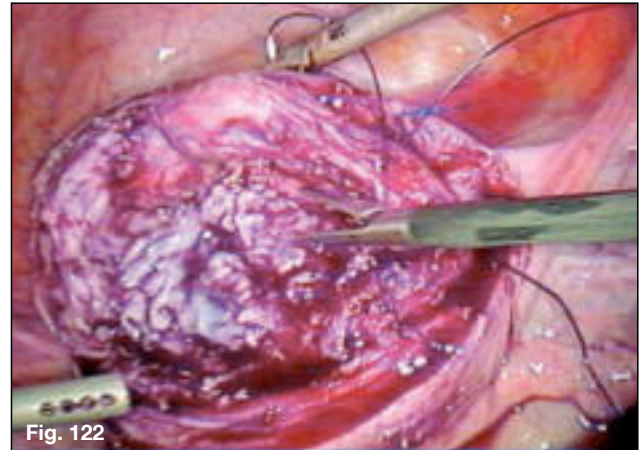


An elliptical incision is made of the myometrium using the ultrasonic hook.

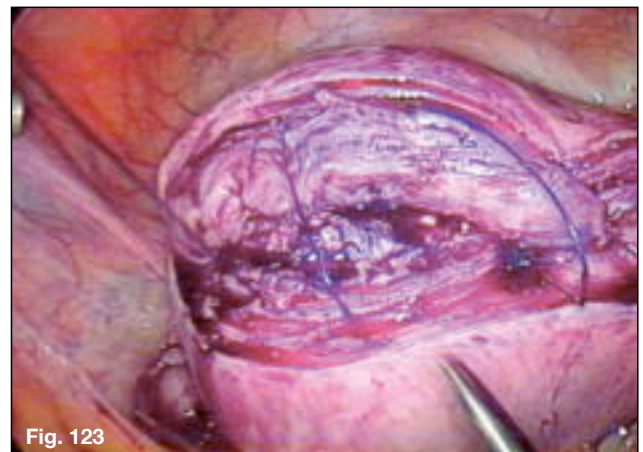


The myomectomy is completed.
Notice the deep muscular area containing the endometrial cavity which is not disturbed.

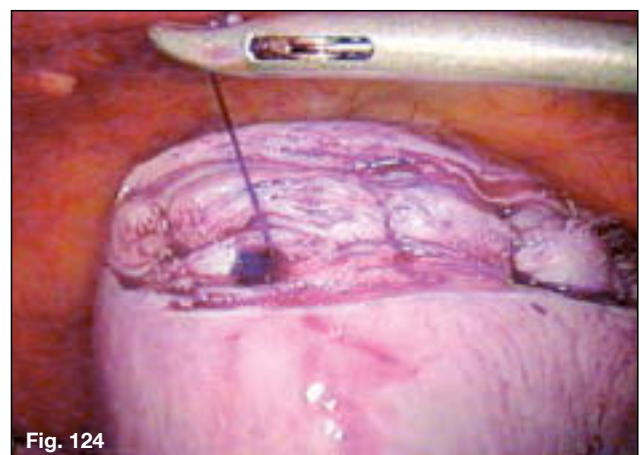
First layer continuous closure using 2-0 PDS with a CT-1 needle, KOH macro needle holder and MANHES grasper.

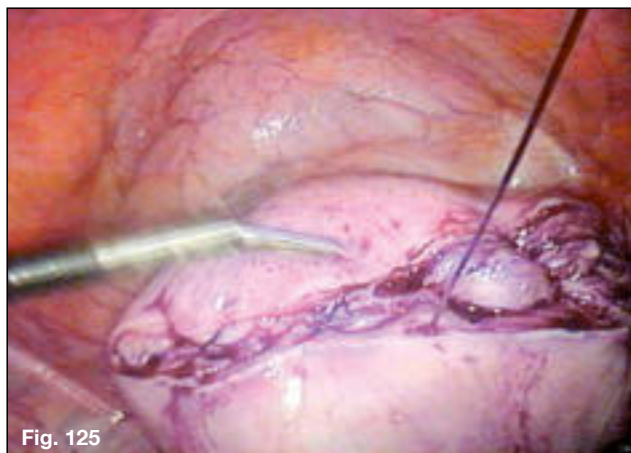


Tightening the first layer.

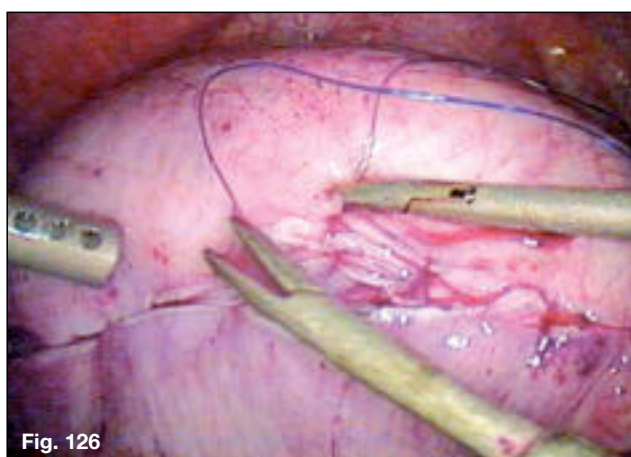


Laparotie is used to maintain tension of this continuous suturing.

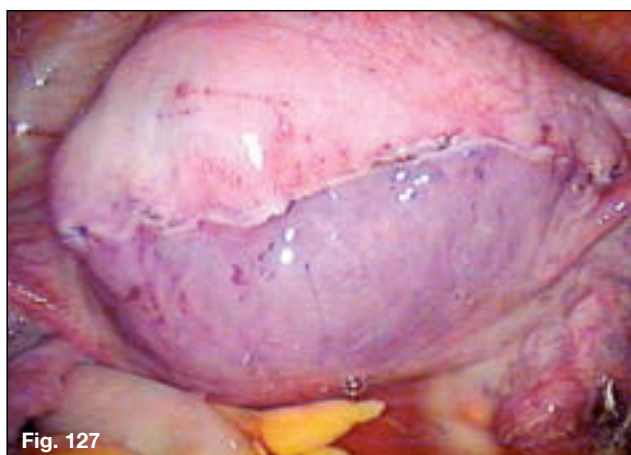




Second layer myometrial suturing is performed using the same suture going back towards the first knot where it is tied.



Subserous 4-0 PDS is used to close the seromuscular layer.

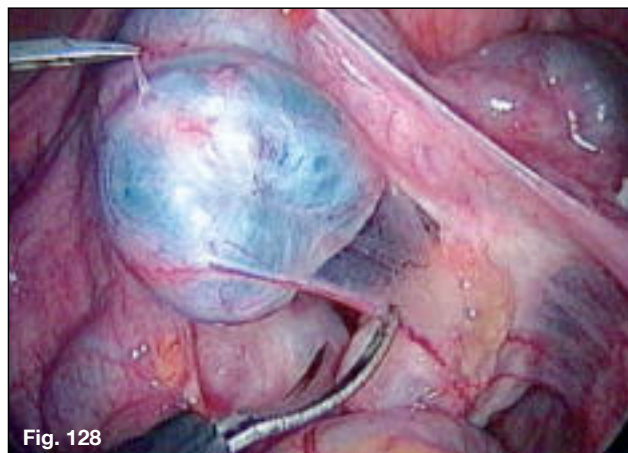


Completed subserous closure with no suture on the outside.

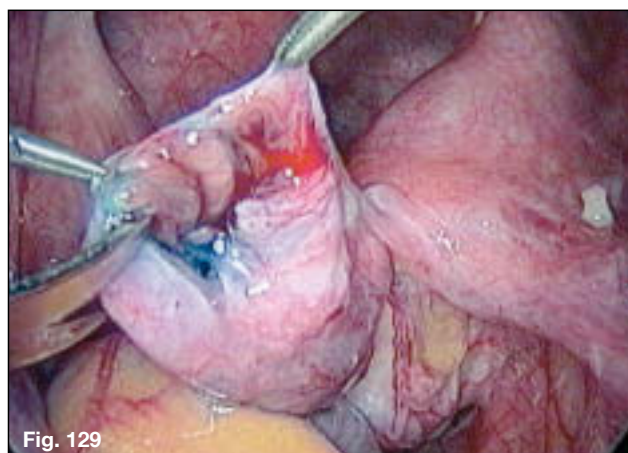
5.8 Neosalpingostomy Hydrosalpinx

This series illustrates the surgeon standing on the patient's left side.

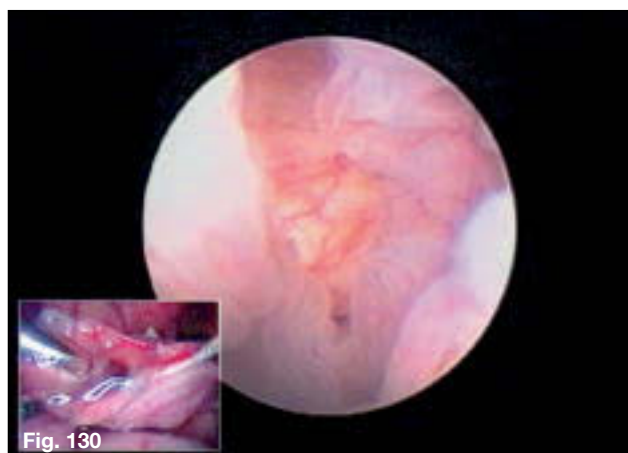
The hydrosalpinx is seen and mobilized.

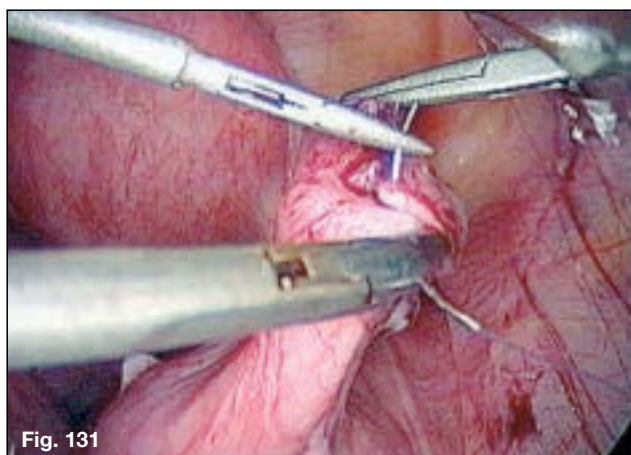


Scissors are used to divide the opening along avascular lines.



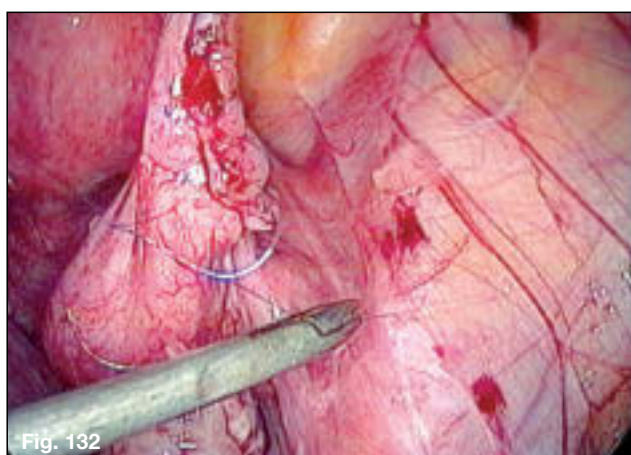
A salpingoscopy is performed that shows normal mucosal folds.



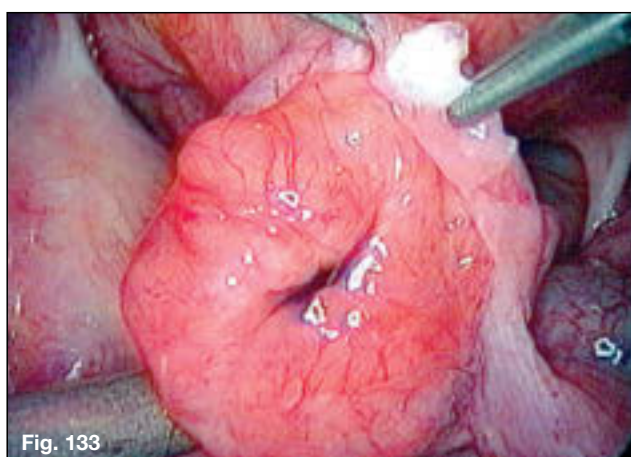


When the surgeon stands on the left side of the patient, the needle traverses vertically upwards. This is in contrast to the needle moving vertically downward when standing on the patient's right side (see **Fig. 75**, page 38).

7-0 PDS is used with ultramicro instrumentation to perform suture eversion.



Further sutures are placed for a total of four.



Neosalpingostomy completed.

Suggested Reading:

KOH, C. ‘*Laparoscopic Microsurgical Tubal Anastomosis*’ In: Endoscopic Management of Gynecologic Disease. Lippincott-Raven Publishers, 1995.

KOH, C. ‘*Tubal Anastomosis by Laparoscopic Microsurgery*’ In: Atlas of Female Infertility Surgery, 3rd Edition, Hunt (at press).

KOH, C. ‘Anastomosis of the Fallopian Tube’ In: Atlas of Laparoscopy and Hysteroscopy Technique, 2nd Edition, Tulandi, 1997.

KOH, C. ‘*Laparoscopic Tubal Reanastomosis*’ In: Endoscopic Surgery for Gynaecologists, Sutton and Diamond, 1997.

KOH, C. ‘*Laparoscopic Microsurgical Tubal Anastomosis: Difficulties and Pitfalls*’ In: Complications of Laparoscopy and Hysteroscopy, 2nd Edition, Corfman, Diamond and DeCherney, 1997.

KOH CH, Janik GM. ‘*The surgical management of deep rectovaginal endometriosis*’ In: Current Opinion Obstet Gynecol 2002; 14(4):357-64.

KOH CH, Janik GM. ‘*Laparoscopic myomectomy: the current status*’ In: Current Opinion Obstet Gynecol 2003; 15(4):295-301.

Laparoscopic Ultramicrosurgery

Basic Set as recommended by
Charles KOH, MD, FRCOG, FACOG

Telescopes and Instruments:

- ① 26003 AA 1

HOPKINS® II Straight Forward Telescope 0°, enlarged view, diameter 10 mm, length 31 cm, autoclavable
- ② 30103 MP 1

Trocar, size 11 mm, including:
Trocar only, with pyramidal tip
Cannula without valve, with insufflation stopcock, length 10.5 cm
Multifunctional Valve, size 11 mm
- ③ 30114 GL 1

Trocar, size 3.5 mm, color code: green, including:
Trocar only, with pyramidal tip
Cannula, length 10 cm, with LUER-Lock connector for insufflation
Silicone Leaflet Valve
- ④ 30361 FA 1

CLICKLINE® rotating KOH Ultramicro I Grasping Forceps, straight, without ratchet, size 3 mm
- ⑤ 30341 FA 1

CLICKLINE® rotating KOH Ultramicro I Grasping Forceps, straight, with disengageable ratchet, size 3 mm
- ⑥ 30361 FR 1

CLICKLINE® rotating KOH Ultramicro I Grasping Forceps, curved right, without ratchet, size 3 mm
- ⑦ 30361 SA 1

CLICKLINE® rotating KOH Ultramicro I Scissors, blunt, without ratchet, size 3 mm
- ⑧ 30361 SB 1

CLICKLINE® rotating KOH Ultramicro I Scissors, sharp, without ratchet, size 3 mm
- ⑨ 26167 ND 1


KOH Ultramicro Unipolar High Frequency Needle, with connector pin for unipolar coagulation, size 3 mm
- ⑩ 30967 KG 1

KOH Ultramicro Guillotine, fine blade for transection, size 5 mm, length 30 cm including:
Handle
Outer tube
Cutter insert
- ⑪ 26167 FN 1

KOH Ultramicro Needle Holder, with tungsten carbide inserts, slightly left curved, straight handle, with ratchet, size 3 mm, length 30 cm
- ⑫ 26167 FK 1

KOH Ultramicro Needle Holder, with tungsten carbide inserts, slightly right curved, straight handle, with ratchet, size 3 mm, length 30 cm
- ⑬ 26167 NA 1

KOH Ultramicro Injection Needle, size 3 mm



The KOH **Laparoscopic Ultramicrosurgery Set** as listed on page 58.



KOH **Macro Needle Holders**

- ① Straight Axial Handle
- ② Pistol Grip Handle

KOH **Macro Needle Holders**

30173 LPO **Dismantling KOH needle holder**, ergonomic pistol grip with disengageable ratchet, ratchet release on top, jaws curved left, with tungsten carbide insert Ø 5 mm, length 33 cm
including:
Insert
Outer tube
Handle

30173 RPO **Same**, with jaws right curved
Also available in 43 cm

30173 LAO **Dismantling KOH needle holder**, ergonomic axial handle with disengageable ratchet, ratchet release on top, left curved jaws, with tungsten carbide insert Ø 5 mm, length 33 cm
including:
Insert
Outer tube
Handle

30173 RAO **Same**, with jaws right curved
Also available in 43 cm

KOH Ultramicro Instruments

Features and Benefits:

- Designed specifically for laparoscopic microsurgery – wide range of precision jaw configurations for full range of applications
- Unique jaw design to maximize ability to hold sutures 6 – 0 to 8 – 0 securely without tearing
- Graduated sheath to maximize durability and deliver unobstructed distal view of anatomy/pathology
- Ergonomic handle, with or without ratchet

The advantages of the KOH Ultramicro Instruments:

- Smaller incisions/less scarring
- Need for suturing during closure is reduced
- Trauma to the abdominal wall is minimized
- Reduces the incidences of trocar site hernias
- Shorter hospital stay/less postoperative pain
- Shorter convalescence
- Comparable results to open laparotomy for tubal anastomosis
- Superior results to thermal techniques

The KOH Ultramicro Series Instruments are suitable for gynecologicreproductive surgical procedures including:



- Tubal anastomosis
- Second look laparoscopic lyses
- Neosalpingostomy
- Ovarian closure following cystectomy
- Barrier membrane suturing
- Ureteral resection and anastomosis for infiltrative endometriosis

The KOH Ultramicro Series Instruments are suitable for urologic procedures such as:



- Ureteral resection and anastomosis
- Ureteral repair
- Vasovasostomy


Grasping Forceps and Scissors, size 3 mm, length 30 cm

CLICKLINE® –rotational, can be dismantled,
Multiple Puncture Approach
for use with trocar size 3.5 mm



Working Length	Handle	
	33161	33141
30 cm		

Single-action jaws:

Number of Outer Sheath with Insert	Catalog number for the complete instrument	
30340 FA	30361 FA	30341 FA
	CLICKLINE® KOH Ultramicro I Grasping Forceps, straight, fine graspers with sub-millimeter jaws for handling 6 – 0 to 8 – 0 sutures without cutting the suture	
30340 FR	30361 FR	30341 FR
	CLICKLINE® KOH Ultramicro I Grasping Forceps, curved right, for ipsilateral suturing technique	

Working Length	Handle
	33161
30 cm	

Single-action jaws:

Number of Outer Sheath with Insert	Catalog number for the complete instrument
30340 SA	30361 SA
	CLICKLINE® KOH Ultramicro Scissors, blunt
30340 SB	30361 SB
	CLICKLINE® KOH Ultramicro Scissors, sharp, rotating

KOH Ultramicro Needle Holders

Size 2 mm

Multiple Puncture Approach
Operating instrument, **length 20 cm and 30 cm**,
for use with trocar size 2.5 mm



30200 FNS



30200 FNS **KOH Ultramicro Needle Holder,**
straight handle with ratchet, length 20 cm

Size 3 mm

Multiple Puncture Approach
Operating instruments, **length 20 and 30 cm**,
for use with trocar size 3.5 mm



26167 FN



26167 FNS **KOH Ultramicro Needle Holder,**
with tungsten carbide insert, slightly left curved,
straight handle with ratchet, length 20 cm

26167 FN **Same,** size 3 mm, length 30 cm

26167 FNL **Same,** size 3 mm, length 36 cm



26167 FKS **KOH Ultramicro Needle Holder,**
with tungsten carbide insert, slightly right curved,
straight handle with ratchet, length 20 cm

26167 FK **Same,** size 3 mm, length 30 cm

26167 FKL **Same,** size 3 mm, length 36 cm

Please note:
Using the needle holders with a needle larger than recommended
may result in mechanical damage to the instrument.

KOH Macro Needle Holders

The ergonomic properties of the new 5 mm KOH macro needle holder allow for precise holding of the needles and the thread. The precision branches and the new locking mechanism enable easy and precise guidance of the needle with threads of thickness 7 – 0 and 0 – 0.

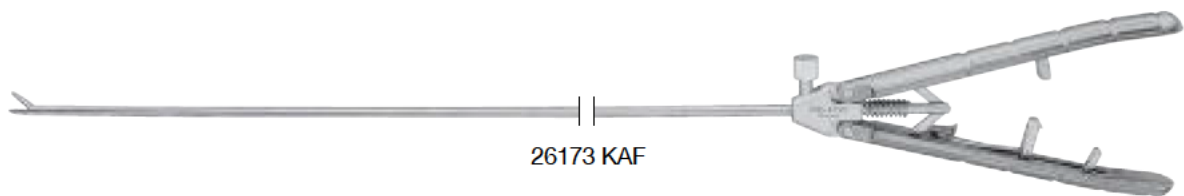
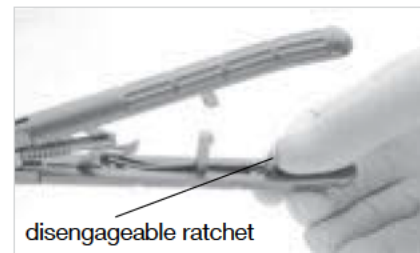
Size 5 mm

Multiple puncture approach

Operating instruments, **length 33**,
for use with trocars size 6 mm or 11 mm with reduction sleeve

Special features:

- Tungsten carbide inserts for firmly and reliably needle positioning as well as long durability
- Easy going, precisely adjustable ratchet for easy and safe positioning of the needle
- Ergonomically designed handle for relaxed work
- Needle sizes BV, SH or CT1




26173 KAF **KOH Macro Needle Holder**, ergonomic axial handle with disengageable ratchet, ratchet release on the right side, straight jaws, size 5 mm, length 33 cm



26173 KAL **Same**, left curved jaws



26173 KAR **Same**, ratchet release on the left side, right curved jaws



26173 KPF **KOH Macro Needle Holder**, ergonomic pistol handle with disengageable ratchet, ratchet release on the left side, straight jaws, size 5 mm, length 33 cm



26173 KPL **Same**, left curved jaws



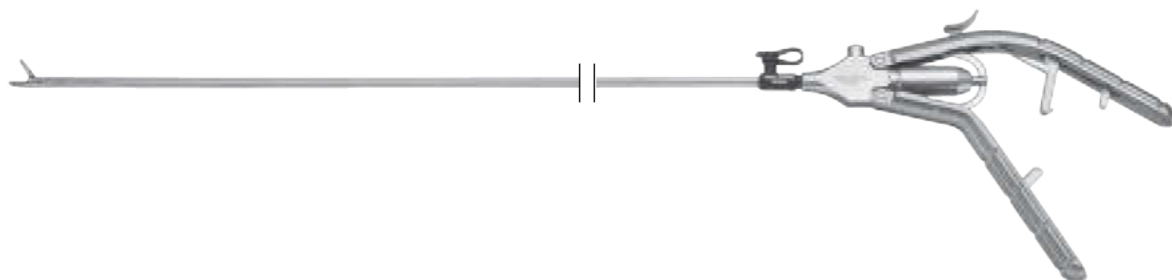
26173 KPR **Same**, ratchet release on the right side, right curved jaws

Please note:

Using the needle holder with a needle larger than recommended may result in a mechanical damage to the instrument.

All of the **KOH Macro Needle Holders** mentioned above are also available with a length of 43 cm (26178 Kxx).

KOH Macro Needle Holder ^{NEW} dismantable



KOH Macro Needle Holder, size 5 mm, dismantling,
including:

- Handle
- Outer Sheath
- Working Insert

Cleaning and sterilization are gaining increasing importance for KARL STORZ as a manufacturer of surgical instruments.

Similar to all our surgical instruments, the cleaning and hygiene of our needle holders also play an important







role. Our KOH macro needle holders feature consistent effectiveness and precision, with significantly improved cleaning results achieved by dismantling the instrument. The handle, outer sheath and inner part can be cleaned and sterilized separately for perfect results.

This unique reusable three-piece design offers the user the following benefits:

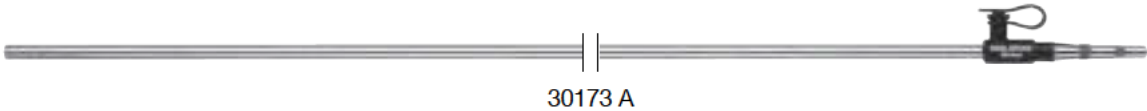
- Can be disassembled into three separate components
- Fully autoclavable
- Cleaning adaptor
- Choice of six different handles and three different working inserts
- With tungsten carbide inserts
- Environmentally correct: In the event of damage, only the component with the defect needs to be replaced
- User-friendly and ergonomic handling

Handles and Outer Tubes *NEW*
KOH Macro Needle Holders, dismantable

Handles axial and pistol grip with disengageable ratchet

		
30173 AR Handle, axial, with disengageable ratchet, ratchet release on the right side	30173 AL Handle, axial, with disengageable ratchet, ratchet release on the left side	30173 AO Handle, axial, with disengageable ratchet, ratchet release on top
		
30173 PR Handle, pistol grip, with disengageable ratchet, ratchet release on the right side	30173 PL Handle, pistol grip, with disengageable ratchet, ratchet release on the left side	30173 PO Handle, pistol grip, with disengageable ratchet, ratchet release on top




Metal Outer Sheath
Size 5 mm






with LUER-Lock connector for cleaning	Length
30173 A	33 cm
30178 A	43 cm

KOH Macro Needle Holder ^{NEW}
dismantable

Size 5 mm

Working Length	Handle		
	30173 AR	30173 AL	30173 AO
33 cm			
43 cm			

Single-action jaws




Insert No.	Complete Instrument		
30173 R	30173 RAR	30173 RAL	30173 RAO
30178 R	30178 RAR	30178 RAL	30178 RAO
	KOH Macro Needle Holder, dismantling, jaws curved to right, with tungsten carbide inserts, for use with suture material size 0/0 to 7/0		
30173 L	30173 LAR	30173 LAL	30173 LAO
30178 L	30178 LAR	30178 LAL	30178 LAO
	KOH Macro Needle Holder, dismantling, jaws curved to left, with tungsten carbide inserts, for use with suture material size 0/0 to 7/0		
30173 F	30173 FAR	30173 FAL	30173 FAO
30178 F	30178 FAR	30178 FAL	30178 FAO
	KOH Macro Needle Holder, dismantling, straight jaws, with tungsten carbide inserts, for use with suture material size 0/0 to 7/0		

KOH Macro Needle Holder *NEW*
dismantable

Size 5 mm

Working Length	Handle		
	30173 PR	30173 PL	30173 PO
33 cm			
43 cm			

Single-action jaws

Insert No.	Complete Instrument		
30173 R	30173 RPR	30173 RPL	30173 RPO
30178 R	30178 RPR	30178 RPL	30178 RPO
	KOH Macro Needle Holder, dismantling, jaws curved to right, with tungsten carbide inserts, for use with suture material size 0/0 to 7/0		
30173 L	30173 LPR	30173 LPL	30173 LPO
30178 L	30178 LPR	30178 LPL	30178 LPO
	KOH Macro Needle Holder, dismantling, jaws curved to left, with tungsten carbide inserts, for use with suture material size 0/0 to 7/0		
30173 F	30173 FPR	30173 FPL	30173 FPO
30178 F	30178 FPR	30178 FPL	30178 FPO
	KOH Macro Needle Holder, dismantling, straight jaws, with tungsten carbide inserts, for use with suture material size 0/0 to 7/0		

Notes:

**WITH COMPLIMENTS OF
KARL STORZ—ENDOSKOPE**